



Archives of The Medicine and Case Reports

Journal Homepage: <https://hmpublisher.com/index.php/AMCR>
eISSN: 2747-2051



Management of Recurrent Congenital Preauricular Fistula: A Case Report

Ermalinda Kurnia^{1*}, Fiona Widayarsi¹, Abla Ghanie¹, Marianne¹

¹Department of Otorhinolaryngology-Head and Neck Surgery, Faculty of Medicine, Universitas Sriwijaya/Dr. Mohammad Hoesin General Hospital, Palembang, Indonesia

ARTICLE INFO

Keywords:

Preauricular fistula
Fistulectomy

*Corresponding author:

Ermalinda Kurnia

E-mail address:

kurniaermalinda@gmail.com

All authors have reviewed and approved the final version of the manuscript.

<https://doi.org/10.37275/amcr.v4i1.265>

ABSTRACT

Congenital preauricular fistula is a malformation of the six auditory hillocks during the development of the auricle when an imperfect fusion of the first arch tuberculum to other tuberculum occurs and generates a tract. The difficulty in the surgical treatment for preauricular fistulas is the high recurrence rate. Surgical techniques were developed and modified to reduce the recurrence rate. This study aimed to describe a recurrent preauricular fistula and its treatment. A 7-year-old patient came to the otorhinolaryngology clinic with complaints of recurrent swelling and discharge on the left preauricular region. Initially, there was only a small hole at the base of the left ear since birth. A thick white discharge appeared and disappeared for 3 months. The lesion was itchy, and the patient frequently scratched it so that the area around the hole became red, swollen, and painful. The patient had undergone surgery for the same complaint in 2016 with a simple fistulectomy. Oral antibiotics were given and planned for fistulectomy under general anesthesia. Evaluation until 3 months postoperatively showed good surgical wounds and non-recurrent infections. In conclusion, the supra-auricula approach had a significantly lower recurrence rate than the sinusectomy approach, and was recommended to make it the standard primary procedure for preauricular sinus excision besides its use in recurrent cases.

1. Introduction

Congenital preauricular sinus is a common congenital malformation of the preauricular soft tissue. This fistula is an incomplete autosomal dominant hereditary disorder that is often found in groups of children as a result of fuse and closure failure from the bulges (hillocks) in the first and second branchial arches, which normally form the auricle during 6 weeks of gestation. The fistula is frequently found on lateral surfaces of the helical arcus and posterosuperior edge of the helix, tragus, or lobule.¹⁻³

The incidence of preauricular fistula in Indonesia is also quite large. A study mentioned the incidence of

cases in 7 years as many as 30 cases of preauricular fistula.⁴ From several studies, it was reported that bilateral lesions were found in 25%-50% of cases, and unilateral lesions were > 50%.⁵⁻⁷ Preauricular fistula is a common case in children. Usually, the abnormality is discovered during a physical examination or after a complication so that the patient comes for treatment. Diagnosis of a preauricular fistula can be confirmed by finding a fistula orifice around the ear that is present from birth. Surgical techniques with a supra-auricular incision approach to expand the operating field and excision of part of the exposed helical cartilage can reduce the recurrence rate. Antibiotic therapy is needed if infection occurs. It is necessary to do



aspiration when there is an abscess. Patients usually come with obstruction and infection of the fistula orifice. If there are no complaints, surgery is not necessary.^{8,9} Complete fistula removal should be done when there are recurrent abscesses and chronic secretion because it will cause a recurrence of infection. The recurrence rate in patients with the standard technique was 32%, while the supra-auricular approach was only 3.7%.^{4,5} This study aimed to describe how to properly diagnose and manage recurrence cases of preauricular fistula.

2. Case Presentation

A 7-year-old patient came to the otorhinolaryngology clinic with complaints of recurrent swelling and discharge on the left

preauricular region. Initially, there was only a small hole at the base of the left ear since birth. A thick white discharge appeared and disappeared for 3 months. The lesion was itchy, and the patient frequently scratched it so that the area around the hole became red, swollen, and painful. There were small holes in both ears that were visible from birth. No trauma history of the ear was found. No discharge was found from the ear canal. The patient had been treated 1 month previously with the same complaint and treated with aspiration and antibiotics. The infection was cured, but a few weeks later, the infection was recurrent, and ulcers appeared. The patient had undergone surgery for the same complaint in 2016 with a simple fistulectomy.

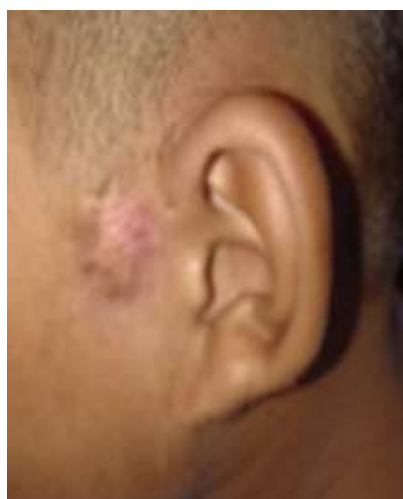

Figure 1. The patient's left ear shows an infected preauricular fistula with a scar after debridement.

On physical examination, the right ear with fistula preauricular was asymptomatic, and the left ear showed swelling in the concha with signs of infection and inflammation around with scar post-debridement. From the fistula orifice, discharge mixed with pus. Tenderness on palpation was found. The ear canal, tympanic membrane, and light reflex were within normal limits. The diagnosis was recurrent infected preauricular fistula sinistra. Oral antibiotics were

given and planned for fistulectomy under general anesthesia.

Intraoperatively, from the orifice of the preauricular fistula, methylene blue was injected to determine the direction of the fistula tract branches. An ellipse incision around the fistula orifice was performed, extending into the supra-auricular. The left preauricular fistula pathway was traced, showing the end of the sinus pathway in the concha auricular



cartilage. After that, a blunt dissection and skin elevation layer by layer were performed, along with tracing the branches of the fistula tract and soft tissue underneath until the fistula can be completely excised with sharp removal of the cartilage part. After complete

excision, interrupted suturing was performed along the incision with 8 sutures of Polyglycolic Acid (PGA) 5.0. The patient was given an initial systemic antibiotic.

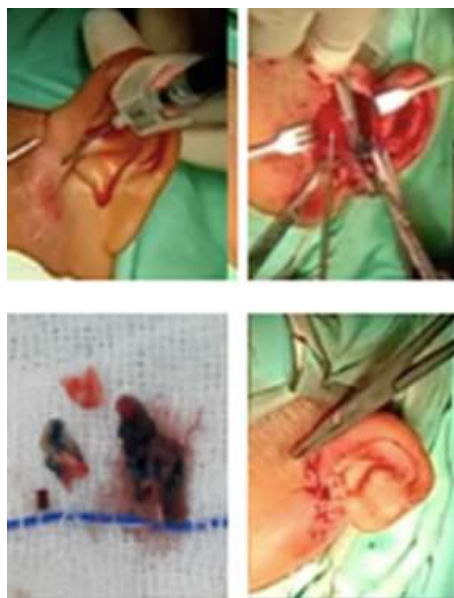

Figure 2. Surgery procedural.

On the second day after surgery, the suture looked good, and therapy was continued. On the third day, sutures looked dry, antibiotic therapy was still ongoing, and analgesics were given if necessary. On the seventh day, sutures also looked dry, antibiotic therapy was continued, and analgesics were given if

needed. After that, the sutures were partially removed. Parents were also educated to make sure their child did not touch her ear. Evaluation until 3 months postoperatively showed good surgical wounds and non-recurrent infections.

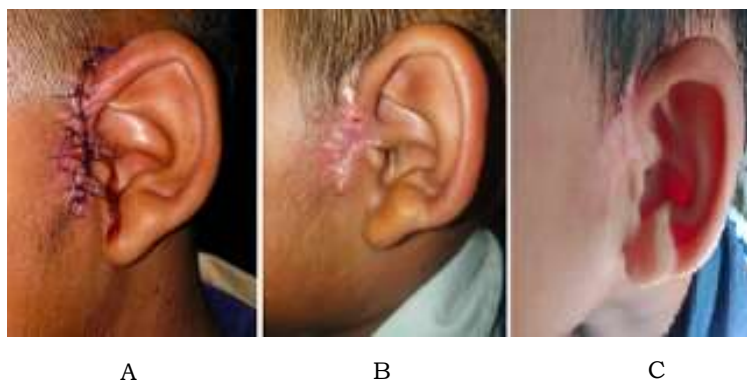


Figure 3. Follow-up post-surgery, (A) 1-day post-surgery (B) 14-day post-surgery, (C) 3 months post-surgery.



3. Discussion

The preauricular fistula is usually found in children. Abnormalities are usually discovered during physical examination or when they seek health care due to complications of the disorder. Theoretically, a preauricular fistula is diagnosed by fistula orifice finding at birth. Furthermore, a preauricular fistula is a congenital abnormality due to the failure of the formation of the outer ear completely. The fluid that comes out from the fistula orifice is produced by the sebaceous gland. A previous study reported that most of the age distribution was 11-20 years (42.3%), with similar distribution between the right and left ear found. The incidence of fistula appearing in both ears was only 11.55%.^{10,11}

Preauricular fistula is an inherited congenital disorder. Preauricular fistula is a congenital abnormality that occurs due to the incomplete fusion of 6 bulges (hillocks) or the trapping of ectoderm epithel during the formation of the outer ear at 6 weeks of gestation. The development of these 6 hillocks will form the outer ear. The first hillock forms a tragus, the second hillock forms a crus helix, the third hillock forms a helix, the fourth hillock forms an anti-helix, the fifth hillock forms an anti-tragus, and the sixth hillock forms the lower lobule and helix. This case showed that there was a possibility of development failure of the second hillock. A preauricular fistula was found with the pit in the central region of the helical shaft.^{6,7}

A classic preauricular fistula is known as a fistula with a pit in the area around the ascending helix in front of the outer ear canal. The variant type described by Choi et al. was also a fistula with a pit in the posterior of the imaginary line that connected the tragus and the posterior side of the ascending helix. The most found location of the pit is in the anterior ascending helix (93.2%), and the second most found is around the posterior surface of the helical shaft or cymba concha. Other locations are the superior portion of the ascending helix, postauricular, and

lobules.^{6,7}

The patient had a fistula removal surgery in 2016 with a simple fistulectomy. Management of this patient is by first giving antibiotics until the infection is relieved, then followed by having fistulectomy surgery. The surgical technique was a supra-auricular approach incision, using methylene blue to trace the tract from the fistula so that it could be completely excised. Part of the helical cartilage was excised to prevent a recurrence. In 3 and 4 months post-surgery evaluation, we found no recurrence. The literature stated that the management of infected preauricular fistula was by giving antibiotics first until the infection was relieved, then followed by fistulectomy surgery. The recurrence rate would be high if the surgery was taken during active infection. The shape of the fistula is small, branching, and meandering, so giving methylene blue is needed to identify the tract of the fistula.⁸

Surgical technique with a supra-auricular approach incision to expand the field of operation and excision of part of the exposed helical cartilage can reduce the recurrence rate. Some studies reported recurrence in patients who underwent fistulectomy. Other studies have recommended using methylene blue or gentle probing to accurately delineate the tract. However, this approach did not guarantee complete tract removal. The reported recurrence was quite high, about 20%.⁸⁻¹⁰

In 1981, Emery and Salama described a wide local excision approach by adding supra-auricular limb incision and performing dissection to the temporalis fascia. The studies stated no recurrences after surgery in 10 out of 10 surgeries using this approach in 2,7 years of follow-up, looking from the tract adherence to the perichondrial auricle. In 1990, Prasad et al. compared simple fistulectomy using a supra-auricular approach (which involved part of the auricular perichondrium). They recorded 42% (n = 12) and 5% (n = 21) incidence of sequence recurrences without specified follow-up time. In 2001, Lam et al. compared



these two techniques and also found out the recurrence of the supra-auricular approach, it was 3.7% (n = 42) versus 32% (n = 25) in simple fistulectomy approach with follow-up time ranged from 36 months to 13 years. This report recorded recurrences of 3 months to 5 years (mean, 6 months) after surgery, which supported the need for long-period postoperative observation to determine an accurate recurrence rate. The supra-auricular approach consists of removing extensive and deep tracts, but cited references do not clearly suggest to do excision on the perichondrium or auricular cartilage in a simple fistulectomy group.¹¹⁻¹⁴

Patient with infected preauricular fistula was given antibiotics first until the infection was relieved, then followed by fistulectomy surgery. The surgical technique was a supra-auricular approach incision, using methylene blue to trace the tract from the fistula so that it could be completely excised. Part of the helical cartilage was excised to prevent a recurrence. The supra-auricular approach had a significantly lower recurrence rate than tract fistulectomy approaches. Thus, it is a good option as a standard procedure for preauricular fistula excision.¹³⁻¹⁷

4. Conclusion

Supra-auricula approach had a significantly lower recurrence rate than the sinusectomy approach and was recommended to make it the standard primary procedure for preauricular sinus excision besides its use in recurrent cases.

5. References

1. Clarke M, Amin K, Kanegaonkar R, Lim J. A pinna helix sinus: a developmental anomaly. *The Otorhinolaryngologist*. 2013; 6(3): 180-1.
2. Hafil AF, Sosialisman, Helmi. Outer ear abnormalities in Soepardi EA, Iskandar N, Bashiruddin J, Restuti RD (Eds.). *Buku Ajar Ilmu Kesehatan Telinga Hidung Tenggorok Kepala dan Leher*, 7thed. Jakarta: FKUI, 2012.
3. Hanson MB, Lucente FE, in P. Ashley Wackym, (Eds.). *Ballenger's otorhinolaryngology head and neck surgery in diseases of the external ear*. 18th ed. USA: PMPH; 2016; 677-707.
4. Gupta R, Agrawal A, Poorey VK. Preauricular sinus: a clinicopathological. *International Journal of Research in Medical Sciences, Int J Res Med Sci*. 2015; 3(11): 3274-7.
5. Bhandari R, Limbu TR, Parajuli RS. Auricular dissection method for treatment of preauricular sinus. *Journal of Chitwan Medical College*. 2014; 4(9): 21-24.
6. Widodo DW, Harba'i HM. Surgical management of preauricular fistula based on plastic-reconstructive algorithm. *Jakarta: ORLI*. 2019; 49(1).
7. Yudhanto D. Management of congenital preauricular sinus. *Jurnal Kedokteran Unram*. 2017; 6(1): 1-7.
8. An SY, Choi HG, Lee JS, Kim JH, Yoo SW, et al. Analysis of incidence and genetic predisposition of preauricular sinus. *Int J Pediatr Otorhinolaryngology*. 2014; 78: 2255-7.
9. Presutti L, Marchioni D. Endoscopic ear surgery: principles, indications, and techniques. *Thieme MedOne Otolaryngology*. 2015; 3: 17.
10. Brujinzeel H, van den Aardweg MT, Grolman W, Stegeman I, van der Veen EL. A systemic review on the surgical outcome of preauricular sinus excision techniques. *Laryngosc*, 2016; 126: 1535-44.
11. Kumari R, Jain RK, Chakraborty P, Pradhan S, Joshi P. Fistular opening below the intertragic notch: a rare variant of preauricular sinus. *J Clin Diagnost Research*, 2016; 10(9): MJ01-MJ02.
12. Kim JR, Kim DH, Kong SK, Gu PM, Hong TU, et al. Congenital periauricular fistulas:



- possible variants of the preauricular sinus. *Int J Pediatr Otorhinolaryngol*, 2014; 78(11): 1843-8.
13. Chowdary KVS, Chandra NS, Madesh RK. Preauricular sinus: a novel approach. *Indian J Otolaryngol Head Neck Surg*, 2013; 65(3): 234-6.
 14. Ruda JM. An unusual case of an infected preauricular pit in a child. *Inf J Pediatr Otorhinolaryngology Extra*. 2015; 91:1-4.
 15. Song-Hwan O, So I-K, Kim J-H. Clinical features of preauricular sinus and recurrence rate of supra-auricular approach. *Indian Journal of Otology*. 2018; 24(2):91-4.
 16. El-Anwar MW, El Aassar AS. Supra-auricular versus sinusectomy approaches for preauricular sinuses. *Int Arch Otorhinolaryngol*. 2016; 20(4): 390-3.
 17. Choo OS, Kim T, Jang JH, Choung YH. The clinical efficacy of early intervention for infected preauricular sinus. *Int J Pediatr Otorhinolaryngol*. 2017; 95: 45-50.

