



Archives of The Medicine and Case Reports

Journal Homepage: <https://hmpublisher.com/index.php/AMCR/index>
eISSN: 2747-2051



Zenker Diverticulum

Adelien Adelien^{1*}

¹Department of Otolaryngology-Head and Neck Surgery, Faculty of Medicine, Universitas Sriwijaya, Palembang, Indonesia

ARTICLE INFO

Keywords:

Zenker diverticulum
Killian's triangle
Endoscopy

*Corresponding author:

Adelien Adelien

E-mail address:

adelien.ent@gmail.com

The author has reviewed and approved the final version of the manuscript.

<https://doi.org/10.37275/amcr.v2i3.27>

ABSTRACT

Zenker Diverticulum is a multifactorial disorder of the Killian's triangle in the hypopharynx characterized by the main symptoms of dysphagia affecting the seventh and eighth decades of age and rarely under 40 years of age. The existence of factors that cause an increase in the intraluminal pressure of the pharynx will lead to the formation of a pocket located in the Killian's triangle, an area with weaker tone of the hypopharyngeal wall and a decrease in relative pressure in the retropharyngeal space. Zenker Diverticulum was first described by Ludlow in 1769, who reported abnormal dilatation of the posterior pharyngeal wall on postmortem examination of a patient who complained a lifelong dysphagia. Zenker Diverticulum is thought to be associated with increasing age in relation to motor muscle coordination for swallowing functions and GERD (gastroesophageal reflux disease). Symptoms include dysphagia, regurgitation, malnutrition, and recurrent aspiration pneumonia. Management includes invasive surgery and non-invasive endoscopy.

1. Introduction

Zenker's diverticulum was first described by Ludlow in 1769, who reported abnormal dilation of posterior pharynx walls at postmortem examinations of patients who complained of dysphagia during life. This condition is characterized by the presence of posterior pharyngeal pouches formed through pulse (hard push) in the Killian triangle area bounded by the inferior pharyngeal constrictor muscles (triopharyngeal muscles) on the left and right sides and next to the causal by the cricopharyngeal muscles resulting in the formation of pockets of the mucosal and submucosal layers. Zenker's diverticulum usually occurs at the age between seven and eight decades of life and rarely occurs before the age of 40. This occurs mainly in men, and the overall prevalence of Zenker Diverticulum

among the general population is believed to be between 0.01% and 0.11%.^{1,2,3,4,5}

Zenker's diverticulum appears to be a multifactorial disorder that is believed to result in increased intraluminal pressure. The factors that triggered the increase in intraluminal pressure are still not fully clear. The most widely accepted theory is the reduced ability of the upper esophageal sphincter (UES) with age, triggering incomplete opening in response to food bolus. This constant pressure on the intralumen is believed to trigger the onset of bags in the Killian triangle area and manifests as Zenker diverticulum. Diagnosis of Zenker diverticulum can be seen based on clinical manifestations. The development of this diverticulum leads to the retention of food particles



leading to complaints of regurgitation, halitosis, aspiration, and difficulty swallowing. In patients with Zenker's Diverticulum, 98% will usually come with a long history of dysphagia followed by a sensation of food stuck in the throat. The management of this condition has changed a lot in line with the benefits and losses incurred from the actions taken. Actions that can be performed can be invasive with surgical or non-invasive techniques with endoscopy.^{4,6,7,8,9}

Zenker's diverticulum

Zenker's diverticulum was first described by Ludlow in 1769, who reported abnormal dilation of posterior pharynx walls at postmortem examinations of patients who complained of dysphagia during life. Zenker's diverticulum was later re-described by Zenker and Von Ziemssens, describing 34 patients with protrusion of the pharynx mucosa on the dorsal, proximal part to the transition from the hypopharynx to the esophagus. It has since been associated with Zenker Von Ziemssens. The location of herniation through suppression in the Killian region, between tyrosopharyngeal fibers and the cryopharyngeal of inferior constrictors, was reported in 1908.^{1,2}

In 1886 Wheeler made his first excision. Several surgical procedures have since been described for the treatment of pharyngeal pouches, including diverticulectomy, diverticulectomy, diverticular inversion, cryopharyngeal myotomy, and endoscopic diverticulotomy. Mosher (1917) was widely recognized as the first person to use endoscopic techniques to treat pharyngeal pouches by dividing the septum between the oesophagus and the pouch. In its publication

Mosher reported good results shown in the four patients who performed this surgical procedure. Eventually he decided to continue with this method until the seventh patient reported experiencing mediastinitis and died. Dohlman re-described and modified endoscopic techniques and reported on 39 patients he had used the procedure since 1935. Dohlman specifically designed it using a double-lipped hypopharyngoscope inserted into the upper lip of the esophagus and a shorter lower lip inserted into the diverticulum, encapsulating the common septum with forceps, and dividing it with diatherrobi blades and electrocautery instruments. By 1960 good results had been reported to increase to 100 cases with a recurrence rate of 7% and no associated deaths or serious complications. The endoscopic method has been modified by inserting an operating microscope, carbon dioxide, and a potassium titanyl phosphate laser (KTP) to divide the muscle septum. As recently as 1993, endoscopic staple diverticulotomy using linear transection and clamping tools was introduced by Martin-Hirsch in England and by Collard, et al in Belgium.^{1,10}

Definition

Zenker's diverticulum is a posterior pharyngeal pouch formed through a pulsi (hard push) in the Killian triangular area bounded by the inferior pharynx constrictor muscle (triofaringeus muscle) on the left and right sides and next to the causal by the krikofaringeus muscle resulting in the formation of pockets of the mucosal and submucosal layers.^{4,6}



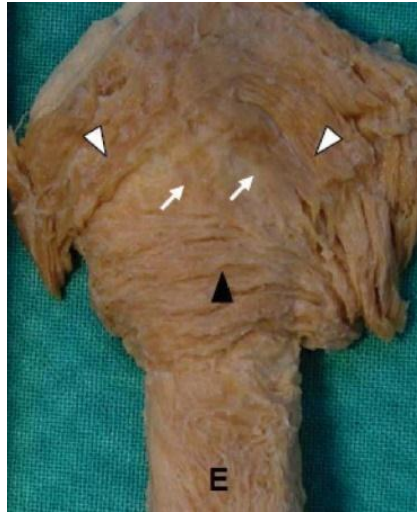


Figure 1. A triangle is formed between the oblique- (white arrowhead) and transverse (black arrowhead) sections of the muscle fibers of the inferior pharyngeal constrictor muscle. The white arrow shows a few irregular muscle fibers in the Killian Triangle. E = esophagus.⁷

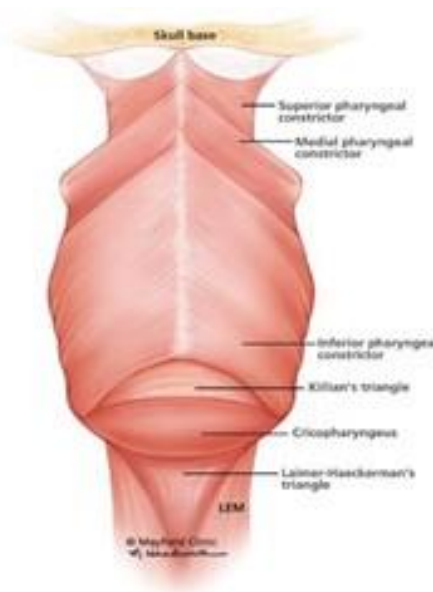


Figure 2. Killian's Triangle Anatomical section of the posterior hypopharynx and esophagus shows a "weak" region formed by the inferior constrictor muscle, cricopharyngeal muscle, and the extrinsic muscle of the esophagus.¹¹

Epidemiology

Zenker's diverticulum usually occurs between the seventh and eighth decades of life and rarely occurs before age 40. This anomaly occurs due to aging, in particular the fibrotic changes and muscle necrosis in the UES. It occurs predominantly in men, and the

overall prevalence of Zenker's diverticulum among the general population is believed to be between 0.01% and 0.11%. Variable incidence has been reported by region, Zenker's diverticulum being more common in Northern than Southern Europe, followed by the United States, Canada, and Australia. The incidence of Zenker's



diverticulum is rarely reported in Japan and Indonesia. The prevalence is difficult to explain due to differences in longevity or anatomical differences in geographic areas. In the UK, the incidence of Zenker's diverticulum is about 2 per 100,000 people per year.^{3,4,5}

Etiology

Although it is widely agreed that the main cause of Zenker's diverticulum is failure of relaxation of the upper esophageal sphincter (UES), resulting in an abnormal increase of pharyngeal intrabolus pressure, as obtained by manometric investigations, Zenker's diverticulum appears to be a multifactorial disorder. Inappropriate contraction of the cricopharyngeal muscle shows structural changes. These changes occur histologically from a combination of changes in the muscle fiber component, an increase in fibrotic tissue, and a significant increase in the ratio of collagen to elastin. The aging process also plays a role due to reduced tissue elasticity and decreased muscle tone. Some researchers postulate an anatomic predisposition. This is reinforced by evidence of rare cases in families plus racial and geographic differences, and is further supported by the results of morphometric and anthropometric studies of Killian's triangle which show the dimensions of the triangle are related to anthropometric appearance. The factors that trigger the increase in intraluminal pressure are still not completely clear. The most widely accepted theory is

that the UES diminishes with age, triggering incomplete opening in response to a bolus of food. Indirect evidence supporting this hypothesis is the replacement of normal muscle and connective tissue of the UES with fibro-adipose tissue, with a continued increase in stiffness. Furthermore, age-related motor incoordination between pharyngeal contraction and relaxation of the UES during swallowing has been documented by some observers and may contribute to high pressure due to the opposing forces acting on the food bolus. Cricopharyngeal muscle spasm and gastroesophageal reflux disease (GERD) are other causative factors that have varied roles. Whether GERD is a cause or effect of Zenker's diverticulum remains unclear and requires further research.^{6,7}

Pathophysiology

As with protrusion of the diverticulum, the main pathogenesis relates to increased intraluminal pressure leading to pocket formation in the area of relative wall weakness compared to the surrounding area. In Zenker's diverticulum, this area of weakness is located in the hypopharynx between two strong pharyngoesophageal muscles, the cricopharyngeal muscle and the inferior pharyngeal constrictor muscle. This area is known as the Killian triangle, an area with weaker tone of the hypopharyngeal wall and a decrease in relative pressure in the retropharyngeal space leading to the formation of a pouch behind it.^{4,7}

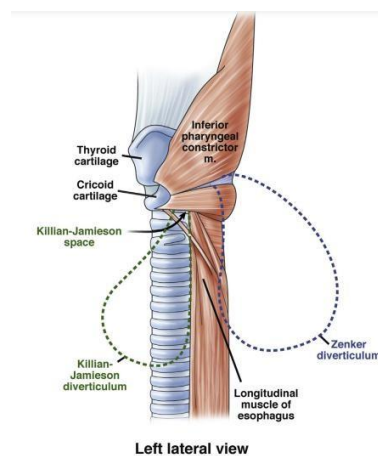


Figure 3. Illustration of Zenker's diverticulum as herniated in Killian's triangle.⁴



The course of Zenker's diverticulum has been accepted as a result of the presence of high intrabolus pressure in the hypopharynx. Theories regarding cricopharyngeal muscle dyscoordination, hyperfunction, or contraction, the contribution of hereditary conditions, and the relationship between reflux and distal stricture of the esophagus and gastroesophageal junction have been widely discussed. However, there is no official consensus by which to discuss the causes of increased intraluminal pressure. This seems to suggest Zenker's diverticulum as a result of a combination of factors. The cricopharyngeal muscle has been shown to play a major role in the formation of the Zenker diverticulum pulsation as the point of restriction in the hypopharynx. These muscles, together with the striated muscles that form the muscularis propria of the upper esophagus and upper esophageal sphincter (UES), are formed from the mesenchymal layers of the branches of the fourth, fifth, and sixth nerve arches. Innervation of the UES then originates from the vagus nerve, the fifth branch of the neural arch, and the recurrent laryngeal nerve, the sixth branch of the neural arch. This explains the relationship between swallowing dysfunction and recurrent laryngeal nerve injury.^{4,7,12}

During normal swallowing, food boluses are detected by glossopharyngeal and vagal afferent fibers in the oropharynx. In the dorsal medulla, nerve synapses from the nucleus tractus solitarius, and interneurons carry signals to the vagal motor nucleus. Efferent signals along the neurons generate inhibitory signals in the cricopharyngeal muscle fibers before the food bolus arrives. Relaxation occurs when the muscles contract and cause the larynx to lift and move forward, exposing the area of the cricopharyngeal muscle. The Upper Esophageal Sphincter (UES) dilates and opens the passage of the food bolus followed by the larynx behind it and closure of the cricopharyngeal muscles. Any disturbance of these mechanisms, mechanical or neurological, can result in increased hypopharyngeal pressure and Killian's triangle.^{4,12}

Clinical overview

Although many different clinical manifestations are shown by patients with Zenker's diverticulum, 80-90% of patients complain of dysphagia. Regurgitation of undigested food, halitosis, and hoarseness may also occur. Borborygmy in the neck can also be found and is a pathognomonic feature of Zenker's diverticulum. As the pouch enlarges, symptoms become more severe with weight loss resulting from malnutrition. As many as 30-40% of patients describe chronic cough and recurrent episodes of aspiration, some with aspiration pneumonia. Symptoms last from weeks to years. A sudden increase in the severity of dysphagia and regurgitation and/or the development of symptoms such as local pain and hemoptysis or hematemesis may indicate the presence of squamous cell carcinoma in Zenker's diverticulum which has an incidence of 0.4–1.5%. Other pathologies associated with Zenker's diverticulum include laryngocele, leiomyoma, polymyositis, cervical esophageal tissue, carotid body tumor, anterior cervical fusion, upper esophageal stenosis, hiatal hernia, and gastroesophageal reflux. This pathology is not directly or caused by Zenker's diverticulum, but can be an additional cause of dysphagia in Zenker's diverticulum patients. Gastroesophageal reflux (GER) has been implicated in the genesis of Zenker's diverticulum based on the fact that Zenker's diverticulum is extremely rare in countries where GER is rare.^{3,13}

Zenker's diverticulum staging

The Lahey, Mortons, and Van Overbeek staging system was used for the evaluation of Zenker's diverticulum. This staging system is used to describe the severity of Zenker's diverticulum, usually based on the size of the pouch. Van Overbeek and Groote used cervical vertebral size as a standard for comparison rather than absolute size measurements. Brombart and Monges expanded the classification into four stages, combining size, appearance, and deglutition stages. Other workers have created increasingly complex categories incorporating elements from the



Brombart and Monges and van Overbeek and Groote systems. Although useful in terms of Zenker's diverticulum classification, this setting has limited

clinical utility. Videofluoroscopy with barium administration is a radiographic method used for staging.^{5,8,14}

Table 1. Zenker Diverticulum staging¹⁴

Researcher	Stage 1	Stage 2	Stage 3	Stage 4
Lahey (1930)	The presence of a small protrusion of the mucosa	Already formed pocket, however hypopharynx and esophagus is still in the place.	Inline hypopharynx With diverticulum, and Esophagus pushed anteriorly.	
Brombart & Monges (1964)	<i>Thornlike diverticulum</i> (axis longitudinal 2-3 mm), only seen in phase <i>upper contraction esophageal sphincter.</i>	<i>Clublike diverticulum</i> (axis longitudinal 7-8 mm), only visible when <i>upper contraction phase Esophagus sphincter.</i>	<i>Bag-shaped Diverticulum</i> (oriented to caudal direction, axis >1cm), none compression on Esophagus	Compression esophagus.
Morton & Bartley (1993)	Small pouch <2 cm	Medium pocket 2-4 cm	Large pouch >4 mm	
Van Overbeek & Groote (1994)	Small sac < 1 vertebral body in length	Medium sac with 1-3 vertebral bodies	Large sac with length >3 vertebral bodies	

Diagnosis

The diagnosis of Zenker's diverticulum can be seen based on clinical manifestations. The development of this diverticulum causes retention of food particles which leads to complaints of regurgitation, halitosis, aspiration, and difficulty swallowing. Patients with Zenker's diverticulum 98% will usually present with a long history of dysphagia followed by the sensation of food being stuck in the throat. Other common symptoms including recurrent cough, halitosis, and unexplained weight loss are also reported by the patient. Rarely, a lump may be seen on the neck. Retention by the diverticula sac causes spontaneous recurrent regurgitation of decaying undigested food which interferes with the patient's feeding process and

causes bad breath. Patients complain of food feels sticky and must be swallowed several times. Choking may occur. If the diverticula increase in size, the patient takes longer to finish eating.^{4,8}

A sudden increase in the severity of dysphagia and regurgitation into alarm symptoms, such as local pain and hemoptysis or hematemesis, may indicate ulceration or squamous cell carcinoma within Zenker's diverticulum which has an incidence of 0.4% to 1.5%. Hoarseness or dysphonia, cough, and unexplained aspiration pneumonia can be found in 30% to 40% of patients. Physical examination findings are few and usually only seen in more severe cases. Usually the patient has findings of malnutrition, voice changes, neck masses, cervical borborygmi and crepitations. In



most cases, the diagnosis of Zenker's diverticulum is suspected based on clinical symptoms and confirmed with a barium esophagram. Large diverticula sacs can be palpated as a soft, doughy cervical mass posterior to the lower part of the sternocleidomastoid muscle, which is usually on the left. Manual pressure on this mass will produce a buzzing sound (gargling) followed by coughing.^{3,4}

Supporting investigation

Barium Esophagram is the gold standard test, barium is preferred over a water soluble agent such as gastrografin because the patient may experience aspiration during this examination. The diverticulum is identified, its size is determined, and the size of the opening is assessed. Nearly 10% of Zenker's diverticulum appear on the right side. A classic Zenker diverticulum will be seen in the midline, at the pharyngoesophageal junction. This classic view is a lateral view which will show the pouch almost at the

level of the fifth and sixth cervical vertebrae. Ultrasonography (USG) is commonly used to assess thyroid nodules. In the case of Killian-Jamieson Diverticulum, ultrasound is important to recognize the possibility that the Killian-Jamieson Diverticulum may resemble a thyroid nodule. Ultrasound has been used to detect Zenker's diverticulum although it is not recommended for routine use. The ultrasound contrast agent is swallowed by the patient, and the patient is scanned. Diverticulum that appears behind the hypopharynx and esophagus will maintain contrast for more than 3 minutes. CT-Scan Esophagography with contrast can easily determine the location, size and shape of the diverticula sac. Axial CT scan can localize the origin of the diverticulum more precisely. The CT scan depicts a lateral pouch projection of the Killian-Jamieson diverticulum originating below the level of the cricoid cartilage. Zenker's diverticulum originates at a higher level and is more posteriorly oriented.^{12,13}

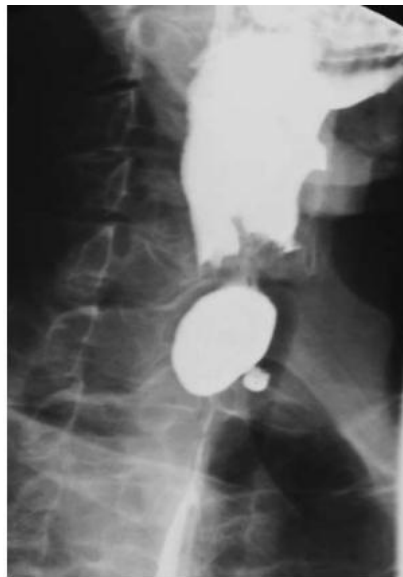


Figure 4. Barium esofagram of Zenker's diverticulum obtained before undergoing flexible endoscopic therapy.³



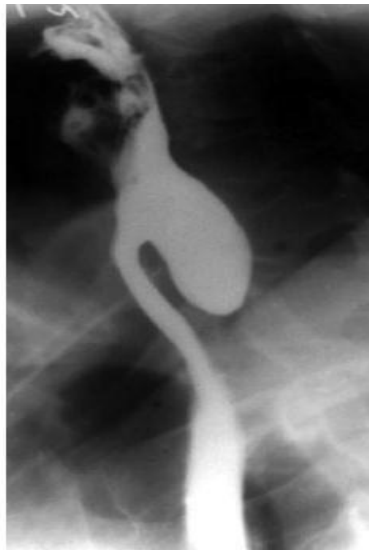

Figure 5. The esophagus of the classical Zenker diverticulum.¹²

Management

Management of Zenker's diverticulum can be divided into operative and non-operative measures. Asymptomatic Zenker diverticulum found at endoscopy does not require treatment. Treatment is needed in

symptomatic cases. Management has evolved from a surgical approach to a less invasive (rigid and flexible) transoral endoscopic technique, with reduced mortality and morbidity and earlier recovery.^{7,9}

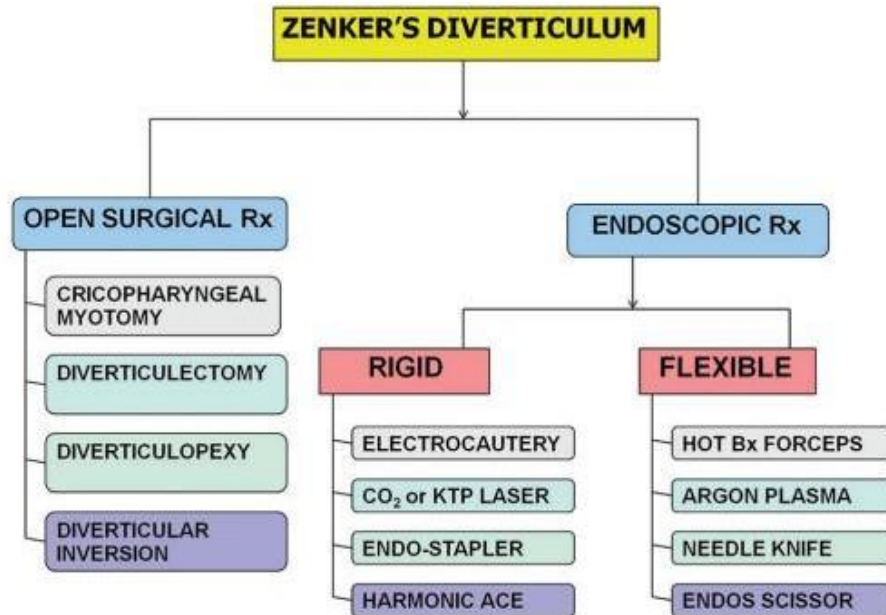


Figure 6. Various treatment modalities can be used in Zenker's diverticulum.⁷

Surgical therapy

The surgery basically involves two stages: treating the diverticulum (by diverticulectomy, diverticulopexy, or inversion) and finding the underlying

pathophysiology of cricopharyngeal dysfunction (by cricopharyngeal myotomy). An external neck incision was made in front of the sternocleidomastoid muscle on the left side, considering the tendency of the



diverticulum to lateralize to this side. Myotomy was performed extending from 2 cm below the inferior constrictor muscle, across the cricopharyngeal muscle to the proximal esophagus (total length of myotomy about 4-5 cm). Based on this size, the pouch can be removed in 3 ways, namely resection (diverticulectomy), suspension, and fixation of the hypopharyngeal wall (diverticulopexy) or invagination into the esophagus itself (diverticula inversion). Larger pockets (>5 cm) are resected, and the defect is closed. Smaller pouches (2-5 cm) can be left hanging, and very small pouches (<2 cm) can be invaginated or left as is. The patient is in the supine position under general

anaesthesia. A 4 cm horizontal incision was made on the left inferolateral side of the cricoid cartilage. The fascia is separated from the sternocleidomastoid muscle and the remaining muscle is incised and the carotid sheath is pulled laterally. Blunt dissection is pulled down into the esophagus and posterolateral to the prevertebral fascia showing a diverticulum. The diverticulum is removed with a Babcock and suspended superolaterally to provide space for the diverticulectomy. Beneath the diverticulum, a dysfunctional cricopharyngeal muscle is visible and myotomy is performed with a new scalpel.^{7,9}

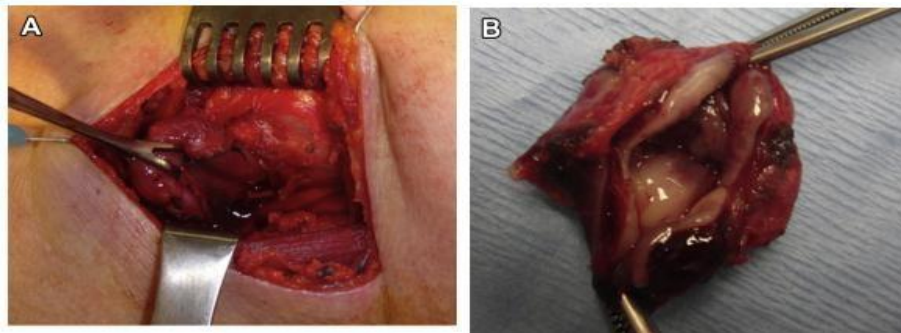


Figure 7. (A) Small Zenker diverticulum hanging by Babcock and (B) interior view of the excised diverticulum.⁹

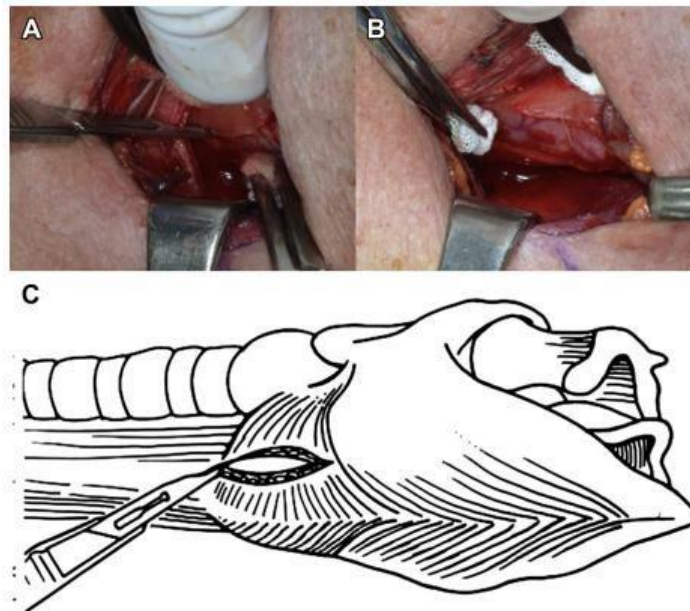


Figure 8. Intraoperative view of (A) cricopharyngeal muscle and (B) myotomy results and (C) cricopharyngeal myotomy scheme.

With surgery, symptoms improve in 90-95% of patients and recurrence is rare. However, pharyngeal pouch surgery has long been associated with complications, partly because of the nature of the surgery itself and partly because of the predominance of comorbid elderly patients. The mortality ratio was 2.3% and radio-morbidity was 10.5%, including 3% recurrent laryngeal nerve injury, 3% leakage and perforation, and 2% cervical infection. Other complications of surgery are local hematoma (1%), respiratory infection (0.3%), esophageal stenosis (0.3%), and mediastinitis (0.2%).

Endoscope

Transoral endoscopy was first introduced by Mosger in 1917 with a rigid endoscope, the transoral endoscopic approach is able to cover some complications due to surgery (such as fistulas, wound

infections, and hematomas) due to minimal external incisions. It is also associated with minimal anesthesia and operating time, and early recovery and discharge from the hospital. This reduces not only hospital costs but also the risk of complications associated with longer stays (hospital-acquired infections, deep vein thrombosis, pulmonary thromboembolism, etc.). The main goal of the transoral endoscopic technique is to divide the septum, separating the diverticulum from the esophageal lumen. This is primarily an internal cricopharyngeal myotomy. The integrity of the diverticulum is lost, triggering a free passage for its contents into the esophagus. The transoral endoscopic technique involves the use of a rigid and flexible endoscope. Rigid endoscopic myotomy was performed by an ENT-TOS surgeon under general anesthesia in the operating room. Flexible endoscopic myotomy is performed by a gastroenterologist under local anaesthesia.^{7,9}

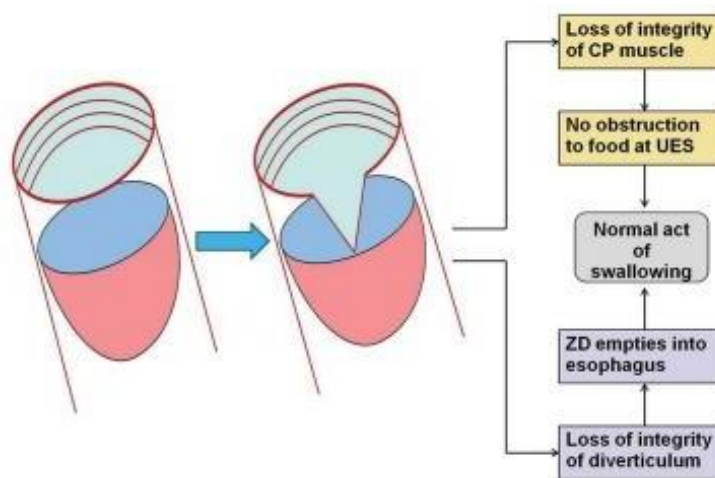


Figure 9. Principles of oral endoscopic therapy for Zenker's diverticulum⁷

An important step in the rigid endoscopic myotomy technique is to visualize and display the septum that separates the diverticulum from the esophageal lumen. Separation of the septum can be done in several ways: Electrocautery, Co2, laser, KTP/532 laser, stapler or Harmonic Ace. Generally, this myotomy is performed electrocautery (Dohlman's technique). However, the

stapler technique has recently become popular because of its advantages. In flexible myotomy, the scope used has a smaller diameter than rigid myotomy, does not require neck hyperextension, and this procedure can be performed in patients who do not allow rigid myotomy due to anatomic factors.^{7,9}



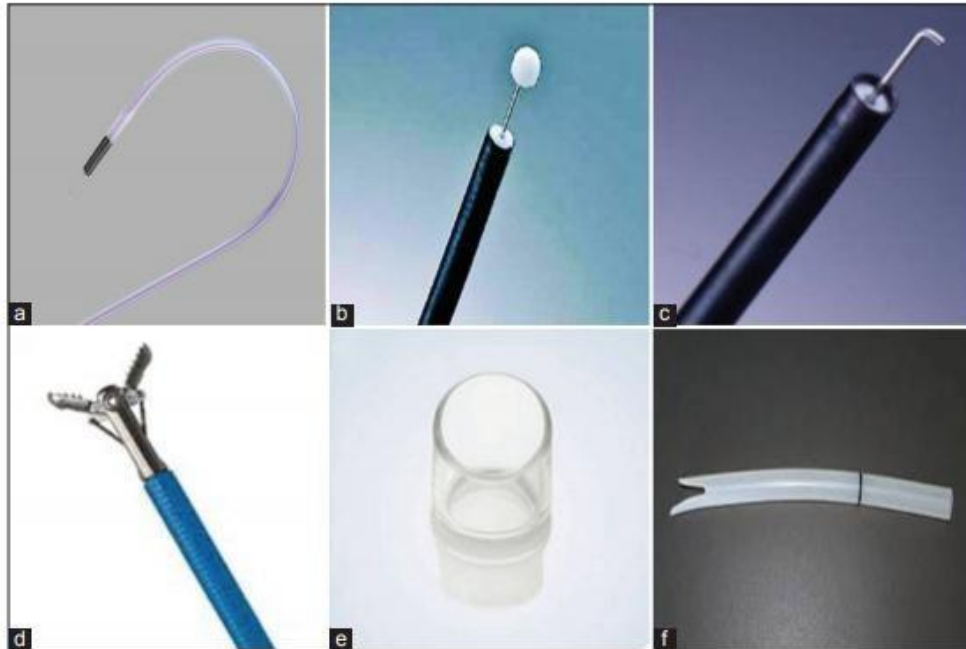


Figure 10. Various accessories used in flexible endoscopic myotomy. (a) shows a standard needle knife (Wilson Cook), (B) shows an insulated tip knife (Olympus), (C) shows a hook knife (Olympus) and (d) shows monopolar forceps, all of which are used to cut the septum. To improve endoscopic visualization, a transparent cap (e) and a soft diverticuloscope (f) can be used.⁷

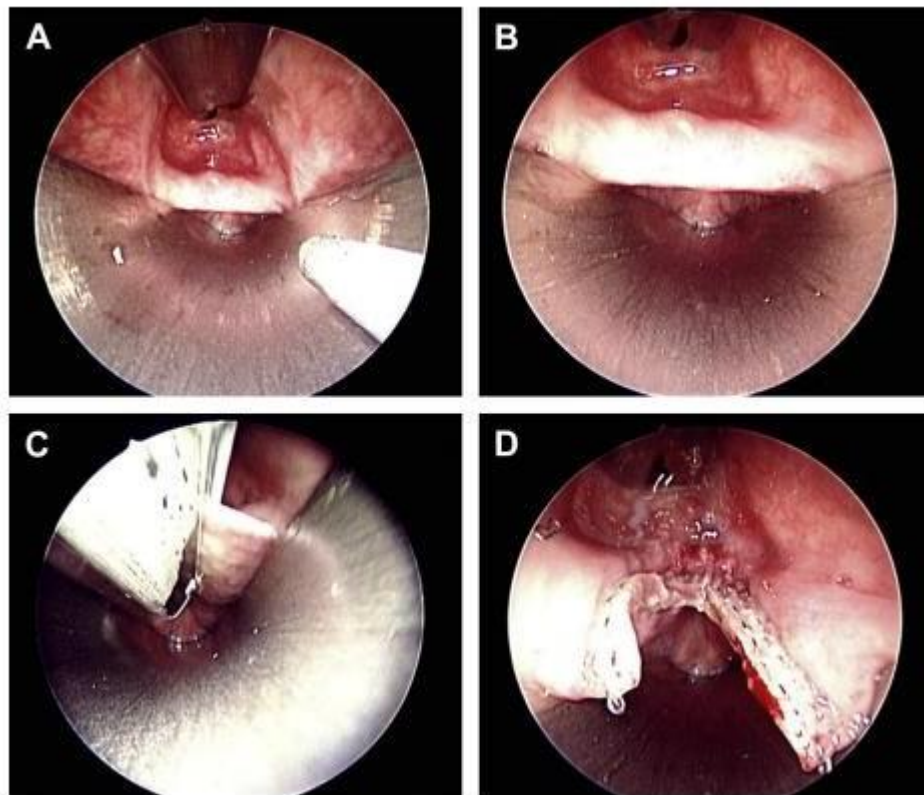


Figure 11. Diverticula view with endoscope under (A) low strength and (B) high strength, (C) insertion of endostapler and (D) post diverticulectomy⁹

The endoscopic technique provides a success ratio with minimal morbidity and therefore complements the management of Zenker's diverticulum with minimally invasive endoscopic techniques. The choice of endoscopic technique will depend on the size of the

diverticulum and the comfort of the surgeon. Surgery is preferred if there is inadequate endoscopic exposure or in situations where multiple recurrences occur from the endoscopic technique.⁹

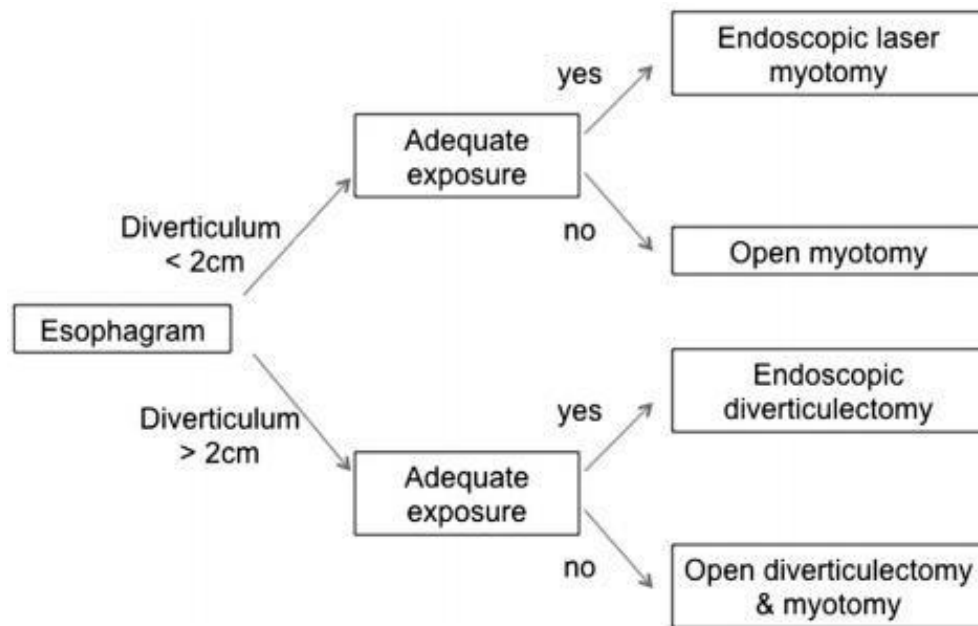


Figure 12. Endoscopic Treatment Algorithm.⁹

Complications

Complications of this disease vary and depend on the surgical approach taken, the age of the patient, and comorbidities. Because the disease is primarily a disease of the elderly, the prognosis is usually poor, and the recurrence rate is high. A serious complication of Zenker's diverticulum is aspiration. Other complications include bleeding, fistula formation with the trachea and esophageal obstruction. Complications following flexible endoscopic therapy of Zenker's diverticulum include those related to sedation, aspiration, perforation, and bleeding. Sore throats are not uncommon and should be anticipated. Perforations can range from subcutaneous or mediastinal emphysema to cervical abscesses and mediastinitis. Uncomplicated cervical or mediastinal emphysema occurs in 0-23% of patients and is a possible microperforation. Air generally clears up in 2-5 days.

Most endoscopes routinely obtain a postprocedural chest X-ray to assess the presence of mediastinal air.^{3,8}

If pneumomediastinum is present, a chest CT scan with oral contrast should be obtained. In clinically stable patients with no mediastinal fluid or contrast leak on CT scan, conservative management with antibiotics and withholding oral intake can be performed. A CT scan should be performed to identify additional symptoms such as fever, tachycardia, leukocytosis, cervical or mediastinal emphysema to identify perforation and the presence of mediastinal fluid. Patients with mediastinal fluid on CT scan require surgical consultation. Patients and clinicians need to be aware of potential complications which include recurrent laryngeal nerve palsy, mediastinitis, esophageal perforation/stenosis, cervical emphysema, and others.^{3,8}



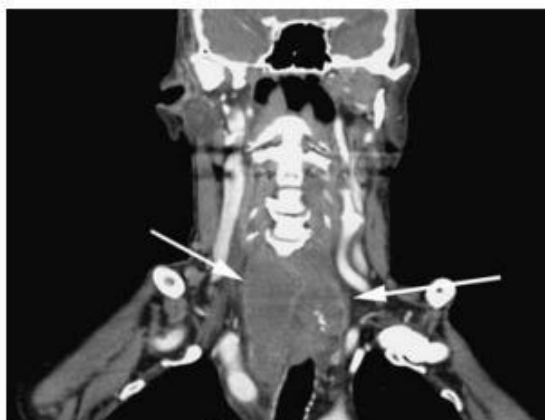

Figure 13. Coronal CT scan of the neck showing an abscess after endoscopic therapy.³

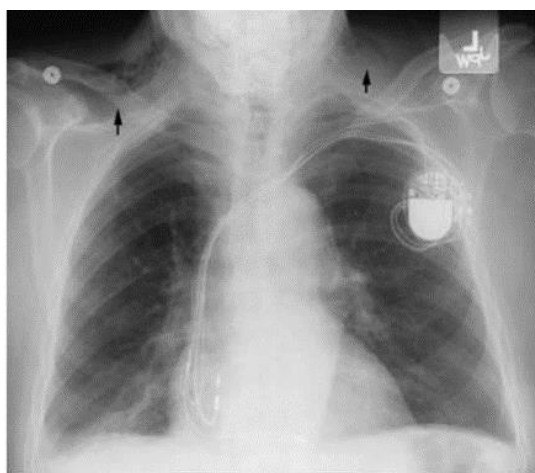


Figure 14. X-ray image of the thorax after flexible endoscopic surgery on Zenker's diverticulum showing subcutaneous emphysema in the cervix.³

2. Conclusion

Zenker's diverticulum has been known since the last 3 decades and still needs further study to understand the disease mechanism, development, examination, appropriate and optimal management to get a better prognosis and avoid other complications. Zenker's diverticulum (ZD) is a disease in the form of a posterior pharyngoesophageal pouch formed by pulsion (pushing) in the Killian triangle area resulting in the formation of pouches from the mucosal and submucosal layers. The most common clinical symptoms found in Zenker's diverticulum are dysphagia, regurgitation of undigested food, malnutrition, and recurrent aspiration pneumonia.

Although it is widely agreed that the main cause of Zenker's diverticulum is failure of relaxation of the

upper esophageal sphincter (UES), it is also stated that the cause of Zenker's diverticulum is a multifactorial disorder. The aging process also plays an important role in the process of Zenker's diverticulum, followed by racial and geographical differences. The factors that trigger the increase in intraluminal pressure are still not completely clear. The most widely accepted theory is that the UES diminishes with age, triggering incomplete opening in response to a bolus of food. Indirect evidence supporting this hypothesis is the replacement of normal muscle and connective tissue of the UES with fibro-adipose tissue, with a continued increase in stiffness. Management of Zenker's diverticulum can be divided into operative and non-operative measures. Asymptomatic Zenker diverticulum found at endoscopy does not require



treatment. Treatment is needed in symptomatic cases. However, the choice of therapy using endoscopy is reported to be more effective because it is minimally invasive.

3. References

1. Siddiq MA, Sood S, Strachan D. Pharyngeal pouch (Zenker's diverticulum). *Postgraduate Medical Journal*. 2001; 77(910): 506-11.
2. Wheeler WI. Pharyngocele and dilatation of the harynx, with existing diverticulum at lower portion of pharynx lying posterior to the oesophagus, cured by pharyngotomy, being the first case of the kind recorded. *Dublin Journal of Medical Science*. 2000; 82: 349-56.
3. Ferreira LEVVC, Simmons DT, Baron TH. Zenker's diverticula: pathophysiology, clinical presentation, and flexible endoscopic management. *Dis Esophagus*. 2008; 21(1): 1-8.
4. Law R, Katzka DA, Baron TH. Zenker's diverticulum. *Clinical Gastroenterology and Hepatology*. 2014; 12(11): 1773-82.
5. Joel AE. Zenker Diverticulum: overview, pathophysiology, etiology. *Medscape*. American Academy of Facial Plastic dan Reconstructive Surgery. 2020.
6. Bizzotto A, Iacopini F, Landi R, Costamagna G. Zenker's diverticulum: exploring treatment options. *Acta otorhinolaryngologica Italica*. 2013; 33(4): 219-29.
7. Dhaliwal HS, Sinha SK, Kochhar R. Endoscopic managemet of zenker's diverticulum. *Journal of Digestive Endoscopy*. 2015; 6(2): 45-54.
8. Nesheiwat Z, Antunes C. Zenker Diverticulum. [Updated 2020 Aug 10]. In: *StatPearls* [Internet]. Treasure Island (FL): StatPearls Publishing; 2021.
9. Prisman E, Genden E. Zenker Diverticulum. *Otolaryngologic Clinic*. 2013; 46: 1101-11.
10. Dohlman G, Mattsson O. The endoscopic operation for hypopharyngeal diverticula: A Roentgen cinematographic study. *Ama Arch Otolaryngol*. 1960; 71: 744-52.
11. Peirlinck, M. Design of biodegradable esophageal stents. gent: University of Gent. 2013.
12. Scher R, David M, et al. Management of Zenker and Hypopharyngeal Diverticula. Springer International Publishing AG; 2018.
13. Sen P, Kumar G, Bhattacharyya AK. Pharyngeal Pouch: Associations and complications. *Eur Arch Otorhinolaryngol*. 2006; 263(5): 463-8.
14. Little, Ryan & Bock, Jonathan. Pharyngoesophageal Diverticuli: Diagnosis, Incidence and Management. *Current opinion in otolaryngology, head and neck surgery*. 2016; 24(6): 500-4.
15. Stewart KE, Smith DR, Woolley SL. Simultaneously occurring zenker's diverticulum and killian jamieson diverticulum: case report and literature review. *The Journal of Laryngology & Otology*. 2017;31(8):661-6.

