

Sub-internal Limiting Membrane Hemorrhage Caused by Heavy Physical Activity

Vera Sumual¹, Ade John Nursalim^{1*}, Andrew Chietra¹

¹Department of Ophthalmology, Prof. dr. R.D. Kandou General Hospital, Manado, Indonesia

ARTICLE INFO

Keywords:

Hemorrhage
Ocular
Subinternal limiting membrane
Vitrectomy

*Corresponding author:

Ade John Nursalim

E-mail address:

dr.adejn@gmail.com

All authors have reviewed and approved the final version of the manuscript.

<https://doi.org/10.37275/amcr.v5i1.448>

ABSTRACT

Sub-internal limiting membrane (sub-ILM) hemorrhage, a rare ocular condition, poses a challenge in ophthalmology due to its association with severe visual impairment. This case report presents a 27-year-old male with a sub-ILM hemorrhage following intense physical activity. Despite unsuccessful Nd:YAG laser treatments, vitrectomy with internal limiting membrane (ILM) peeling resulted in a remarkable improvement in visual acuity from hand movement to 6/6 within the first day post-surgery. The fundus photograph and OCT findings illustrated restored macular anatomy, highlighting the positive outcomes of surgical intervention.

1. Introduction

Sub-internal limiting membrane (sub-ILM) hemorrhage is a relatively rare ocular condition and presents as a distinctive challenge in ophthalmology due to its association with severe visual impairment. While ocular hemorrhages are not uncommon, the occurrence specifically within the sub-ILM space is considered rare, contributing to its clinical significance.¹ The internal limiting membrane, a delicate structure separating the vitreous from the retina, plays a crucial role in maintaining retinal integrity and normal retinal development.² Existing literature acknowledges the scarcity of reported cases involving sub-ILM hemorrhage, making each documented instance a valuable contribution to the understanding of its etiology, presentation, and

management. The main causes of reported sub-ILM hemorrhage include Valsalva retinopathy, blood dyscrasia, Terson syndrome, and ruptured retinal macro-aneurysm.^{1,3,4}

Diagnosis of sub-ILM peeling is challenging. The closest differential diagnosis is sub hyaloid hemorrhages.⁵ When hemorrhage occurs in this confined space, the potential for severe visual loss escalates, underscoring the need for heightened awareness and understanding of this phenomenon. Spontaneous resorption of the blood entrapped in the sub-ILM space tends to be slow and may result in irreversible retinal damage and long-standing visual impairment.^{6,7} In this case report, we present the case of a patient with a sub-internal limiting membrane (sub-ILM) haemorrhage due to intense physical



activity. The haemorrhage was managed through a vitrectomy with the internal limiting membrane (ILM) peeling, yielding a satisfactory outcome within the first day.

2. Case Presentation

A 27-year-old male presented with a sudden onset of severe visual impairment following strenuous physical activity. He reported engaging in weightlifting at a gym, a likely contributor to the development of the haemorrhage. After the mentioned physical activity, there was a rapid and significant decrease in visual acuity, starting from the center of vision. The patient sought medical attention three weeks later, reporting remarkable vision loss in the right eye and limited hand movement in the left eye. Figure 1 shows the fundus photograph captured before the surgery, revealing blood accumulation on the macula. A slight reflection of the membrane is also evident, indicating the presence of the internal limiting membrane layer

covering the blood. In contrast, Figure 2 illustrates the optical coherence tomography (OCT) findings, demonstrating hyperreflectivity in the macular area, thereby describing hemorrhage in the innermost layer of the retina.

The patient received two consecutive laser treatments. Following a week with no observed change in the condition, the patient underwent a vitrectomy. During the surgical procedure, hyaloid membrane detachment was induced (Figure 3). Triamcinolone staining of the internal limiting membrane (ILM) was performed (Figure 4), and the surgery continued with the meticulous peeling of the ILM (Figure 5). These interventions led to remarkable outcomes, with post-surgery vision improving from hand movements to 6/6. Figures 6 and 7 illustrate the fundus photograph and OCT after the surgery, highlighting the positive outcomes. The fundus photograph depicted a clear macula, a finding confirmed by the OCT results.

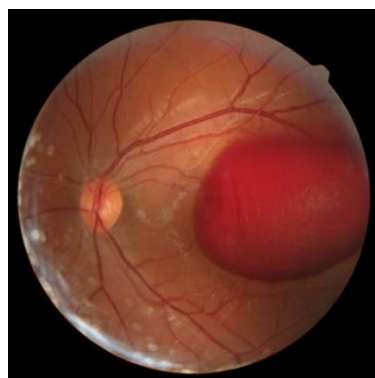


Figure 1. Fundus photograph before surgery.

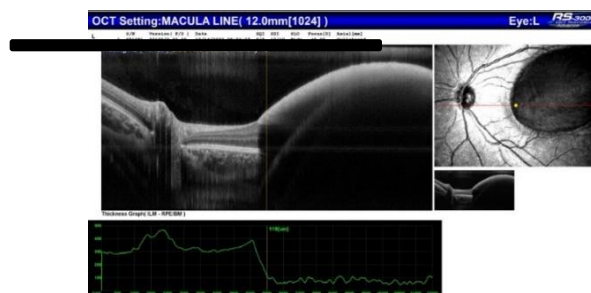


Figure 2. OCT findings before surgery.



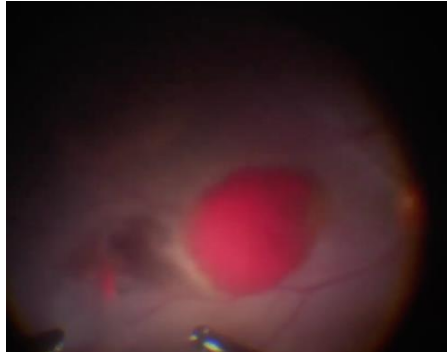


Figure 3. Membrane hyaloid detachment was induced during the surgery.

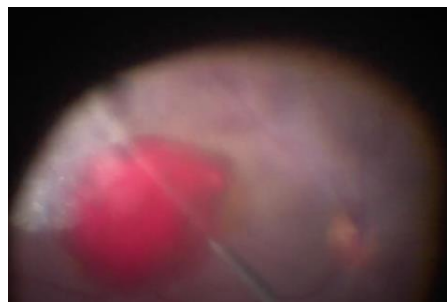


Figure 4. Triamcinolone intravitreal injection to stain the internal limiting membrane.

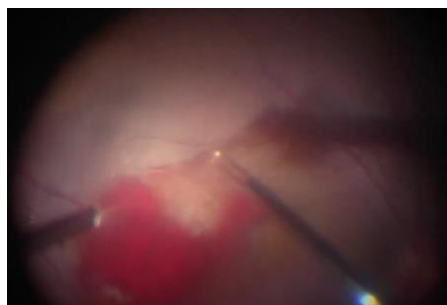


Figure 5. Internal limiting membrane peeling with 23G forceps.

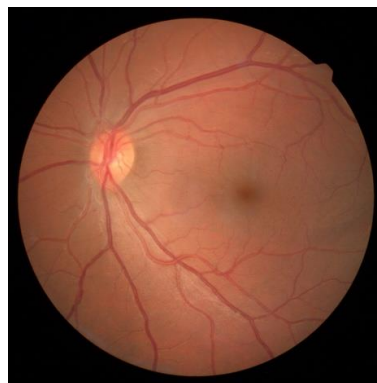

Figure 6. Fundus photograph after the surgery.



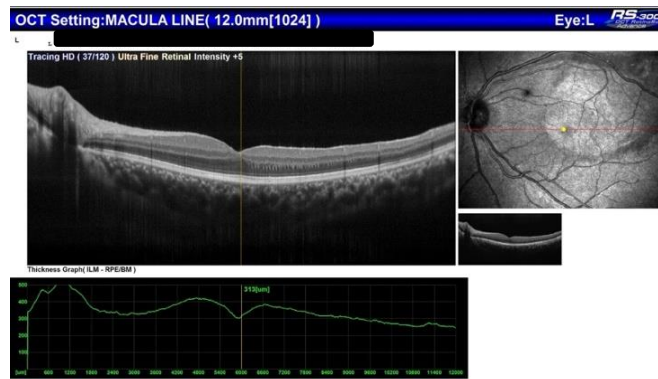


Figure 7. OCT finding after surgery.

3. Discussion

Sub-ILM hemorrhage, while uncommon, can manifest in the retina, especially among individuals in a younger age group. Reported etiologies include Valsalva retinopathy, blood dyscrasia, Terson syndrome, and the rupture of a retinal macroaneurysm. These various factors contribute to the occurrence of sub-ILM hemorrhages, emphasizing the importance of considering multiple potential causes in the diagnostic process. Despite its rarity, awareness of such etiologies is crucial for accurate diagnosis and effective management in the younger population presenting with sub-ILM hemorrhages.^{3,4}

Diagnosing sub-ILM hemorrhage shares similar clinical features with sub-hyaloid hemorrhages, presenting a challenge in differentiation between the two. A notable clinical characteristic is the observation of a double ring appearance in some cases during fundus examinations. This distinct feature arises from the anatomical relationship between the hyaloid membrane and the internal limiting membrane (ILM). The presence of this double-ring appearance serves as a valuable clinical indicator, aiding in the identification and differentiation of sub-ILM hemorrhages from sub-hyaloid hemorrhages.⁶ Sub-ILM hemorrhages manifest as sharply defined, dome-shaped hemorrhages with glistening light reflecting from the internal limiting membrane (ILM). Clinically, blood within the Sub-ILM space exhibits limited

mobility, resulting in apparent immobilization during head movements, particularly when the patient is examined with an indirect ophthalmoscope in a supine position.⁴

OCT serves as a diagnostic tool for assessing the patient's condition. Despite the enhanced capabilities of spectral domain (SD) OCT in visualizing retinal layers, pinpointing specific findings in OCT fundus imaging poses a challenge. Although SD-OCT provides superior resolution compared to the older time-domain (TD) technology, discerning the subtle nuances associated with the double-ring appearance in cases of sub-ILM hemorrhage remains a complex task.⁸ Despite the improved image production, interpreting OCT findings can be challenging. High reflectivity resulting from blood accumulation can blur the boundary lines between inner retinal layers, thereby increasing the difficulty of distinguishing between the hyaloid and ILM layers.⁹

Hemorrhages smaller than one disk diameter often exhibit a tendency to resolve spontaneously within a brief timeframe.⁷ The patient sought medical attention three weeks after experiencing visual deterioration, with no spontaneous resolution evident. Subsequently, the patient underwent Nd:YAG laser treatment twice. Despite receiving consecutive treatments, no visible anatomical or functional changes were observed. Coagulated blood under ILM does not easily resorb or drain using Nd:YAG laser.



Moreover, intent Nd:YAG laser membranotomy can induce persistent premacular cavity, macular hole, retinal detachment even formation of epiretinal membrane.⁷

The patient underwent vitrectomy after experiencing failure with a couple of Nd Yag therapies, which was the chosen treatment. The surgery confirmed the diagnosis of sub-ILM hemorrhage. A case series on Valsalva retinopathy also reported the ineffectiveness of Nd Yag laser in cases of sub-ILM hemorrhages.⁷ Until now, there is no clear explanation about the effectiveness of the Nd Yag laser on the hyaloid membrane compared to the internal limiting membrane (ILM). However, Nd Yag laser has the potential for severe adverse effects on the retina from full-thickness macular hole¹⁰, epiretinal membrane formation¹¹, premacular cavity¹² to retinal detachment¹⁰. This should be taken into consideration when considering Nd Yag as a treatment option. Moreover, Nd Yag tends to have low to no effectiveness in cutting the internal limiting membrane (ILM), unlike its notable effectiveness on the hyaloid membrane.

The vitrectomy procedure commenced with core vitrectomy and detachment of the posterior hyaloid (Figure 3). Despite the hyaloid detachment, the hemorrhages persisted within a constricted ILM layer. After that, an intravitreal injection of Triamcinolone was administered to stain the ILM (Figure 4). Once a clear view of the ILM was achieved, ILM peeling was performed to alleviate the presence of blood (Figure 5). Another scientific report supports the idea that the most reliable method for diagnosing sub-ILM peeling is through surgical confirmation.¹³ This is because, with surgery, we can meticulously peel each membrane to pinpoint the exact location of the hemorrhages.

A significant improvement in visual function was noted before and after vitrectomy, with visual acuity dramatically improved from hand movement to 6/6 on the first-day post-surgery. Anatomical evidence from

fundus photographs and OCT findings further suggests a restored macular anatomy. This leads to the conclusion that surgical intervention in the case of sub-ILM hemorrhages has a satisfactory and spontaneous positive effect on visual acuity. Other reports also support this finding.^{7,13}

4. Conclusion

This case emphasizes the efficacy of vitrectomy with ILM peeling as a successful therapeutic approach for sub-ILM hemorrhages. Despite challenges in diagnosis and potential risks associated with Nd: YAG laser treatments, surgical confirmation remains the most reliable method. The positive visual and anatomical outcomes underscore the importance of timely and precise interventions in managing sub-ILM hemorrhages, providing valuable insights for future cases.

5. References

1. Chou YK, Huang YM, Lin PK. Sub-internal limiting membrane hemorrhage treated with intravitreal tissue plasminogen activator followed by octafluoropropane gas injection. *Taiwan Journal of Ophthalmology*. 2015; 5(4): 198-201.
2. Zhang KY, Johnson TV. The internal limiting membrane: roles in retinal development and implications for emerging ocular therapies. *Experimental Eye Research*. 2021; 206: 108545.
3. Chou YK, Huang YM, Lin PK. Sub-internal limiting membrane hemorrhage treated with intravitreal tissue plasminogen activator followed by octafluoropropane gas injection. *Taiwan J Ophthalmol*. 2015; 5(4): 198-201.
4. De Maeyer K, Van Ginderdeuren R, Postelmans L, Stalmans P, Van Calster J. Sub-inner limiting membrane haemorrhage: causes and treatment with vitrectomy. *Br J Ophthalmol*. 2007; 91(7): 869-72.



5. Shukla D, Naresh KB, Kim R. Optical coherence tomography findings in Valsalva retinopathy. *Am J Ophthalmol.* 2005; 140(1): 134-6.
6. Zhang Y, Li J, Cao X, Zhou H, Jia L, Gao L, et al. Efficiency and complication of 577-nm laser membranotomy for the treatment of retinal sub-inner limiting membrane hemorrhage. *Frontiers in Ophthalmology.* 2022; 2.
7. García Fernández M, Navarro JC, Castaño CG. Long-term evolution of Valsalva retinopathy: a case series. *J Med Case Rep.* 2012; 6: 346.
8. Kostanyan T, Wollstein G, Schuman JS. New developments in optical coherence tomography. *Curr Opin Ophthalmol.* 2015; 26(2): 110-5.
9. Blaise P, Duchateau E, Comhaire Y, Rakic JM. Optical coherence tomography in the diagnosis of premacular hemorrhage. *Retina.* 2006; 26(2): 232-4.
10. Ulbig MW, Mangouritsas G, Rothbacher H-H, Hamilton AP, McHugh JD. Long-term results after drainage of premacular subhyaloid hemorrhage into the vitreous with a pulsed Nd: YAG laser. *Archives of Ophthalmology.* 1998; 116(11): 1465-9.
11. Kwok AK, Lai TY, Chan NR. Epiretinal membrane formation with internal limiting membrane wrinkling after Nd: YAG laser membranotomy in Valsalva retinopathy. *American journal of ophthalmology.* 2003; 136(4): 763-6.
12. Meyer CH, Mennel S, Rodrigues EB, Schmidt JC. Persistent premacular cavity after membranotomy in Valsalva retinopathy evident by optical coherence tomography. *Retina.* 2006; 26(1): 116-8.
13. Hussain RM, Dubovy SR, Zhou XY, Schwartz SG, Villegas VM. Pars plana vitrectomy with intraoperative optical coherence tomography for sub-internal limiting membrane fibrosis excision in a child with Terson syndrome: Surgical and pathological correlation. *American Journal of Ophthalmology Case Reports.* 2019; 15: 100479.

