




Archives of The Medicine and Case Reports

Journal Homepage: <https://hmpublisher.com/index.php/AMCR/index>
eISSN: 2747-2051



Decompensated Acute Heart Failure Accompanied with Cardiac Cirrhosis and Chronic Disease Anemia in Child

Tommy Darmasaputra^{1,2*}

¹ General Practitioner, Tanjung Batu Community Health Service, Berau, Indonesia

² Faculty of Medicine, Universitas Kristen Krida Wacana, Jakarta, Indonesia

ARTICLE INFO

Keywords:

Heart failure
Portal vein
Chronic
Disease
Hyperemia

*Corresponding author:

Tommy Darmasaputra

E-mail address:

tommy_darma@yahoo.com

The author has reviewed and approved the final version of the manuscript.

<https://doi.org/10.37275/AMCR.v1i2.6>

ABSTRACT

Continuous heart failure can lead to complications to other systems, one of which is the hepatic system. Heart failure results in venous congestion in the portal vein so that the portal vein pressure increases, which is called portal hypertension. Portal hypertension causes fluid to pass through the walls of blood vessels and into the tissues. Management of decompensatory heart failure accompanied by comorbid disease in cardiac cirrhosis includes drugs management that does not aggravate the liver, namely angiotensin converting enzyme inhibitors and loop diuretic agents. Also, non-pharmacological management such as resting position and a diet sufficient in protein and low salt help improve the patient's general condition. This case report aims to present a compensated heart failure accompanied by cardiac cirrhosis and anaemia of chronic disease in a child.

1. Introduction

Congenital heart disease is the most common congenital disorder, covering nearly 30% of all congenital disorders. It can be classified into two groups, namely non-cyanotic and cyanotic congenital heart disease. The number of patients with non-cyanotic congenital heart disease is much greater than cyanotic, ranging from 3 to 4 times. One of the non-cyanotic congenital heart diseases is the patent ductus arteriosus (PDA). PDA is the fifth most common congenital heart defect or 8-10% of all congenital heart defects cases. In the United States, it is estimated that out of 1000 live births, 1 PDA case is found. Girls' ratio to boys is 2:1, and cases tend to increase in the patient's relatives. Approximately 75% of cases occur in

infants born weighing <1200 grams and often with another congenital heart disease.^{1,2} Continuous heart failure can lead to complications to other systems, one of which is the hepatic system. Heart failure results in venous congestion in the portal vein so that the portal vein pressure increases, which is called portal hypertension. Portal hypertension causes fluid to pass through blood vessels and tissues. Another cause of portal hypertension is the destruction of hepatocytes in the liver. There are stellate cells in the liver between the hepatocyte and sinusoid cells or what is called the perisinusoidal space. These cells are quiescent or inactive conditions, but they can function as a reserve of vitamin A. In damaged hepatocytes, stellate cells will be activated, which will then produce TGF- β and



collagen protein. These will accumulate and make the perisinusoidal space enlarge, then compress the sinusoids, causing portal hypertension. One of the functions of the liver is producing albumin. If there is liver damage, hypoalbuminemia must be distinguished from hypoalbuminemia due to liver damage or kidney damage resulting in proteinuria.^{3,4} Also, patients may appear jaundiced due to decreased conjugate function of bilirubin. This case report presents heart failure in a child followed by complications of cardiac cirrhosis and anaemia of chronic disease.

2. Case Presentation

A girl, 12 years old, student, Islam religion, middle-down socioeconomic background, live in an urban area, came to the Balikpapan Regional hospital's emergency unit with shortness of breath complaints. Shortness of breath appears suddenly and has been felt for the last two weeks. This complaint is felt continuously throughout the day and does not improve with rest. Besides, the patient also complained of an enlarged leg and stomach since the previous two weeks. The patient does not know which abdomen or legs are enlarged first. There are no complaints of pain in the legs and

stomach. The patient also complained of coughing from 1 week before. Initially only cough with phlegm, but in the last three days coughing there was fresh red blood. The patient admits that sometimes there are night sweats, but there is no weight loss. There are no complaints of fever and colds.

On vital sign examination, the results were within normal limits. There is also anaemic conjunctiva and sclera jaundice. Examination of the patient's heart found cardiomegaly. There was a pathological heart sound of a grade III/VI diastolic murmur on the ICS IV midclavicular line and parasternal left line. Abdominal examination revealed hepatosplenomegaly and ascites. There is pitting oedema in both legs.

From the initial investigations that have been carried out, the complete blood count and blood chemistry checks showed a hemoglobin level of 8.6 g/dL (standard 12.0-15.0 g/dL), hematocrit level 31.8% (standard 35-49%), MCV 66. fL, MCH 17.9 pg, MCHC 27.0 g/dL (microcytic hypochromic anemia) and albumin 2.7g/dL (hypoalbuminemia). Massive cardiomegaly and signs of congestive heart failure were found (Figure 1).

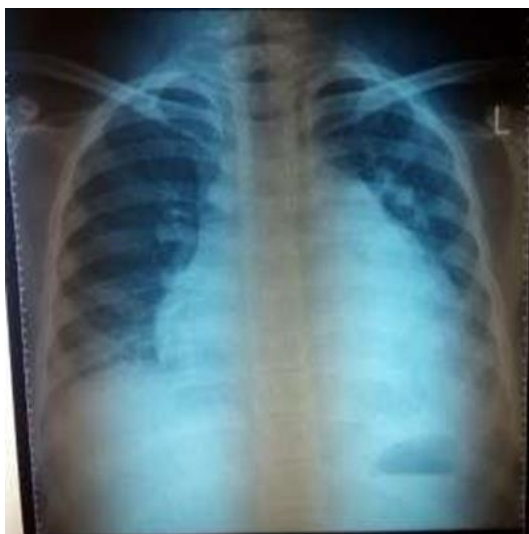

Figure 1. X-ray imaging posteroanterior.

This patient was diagnosed as congestive heart failure et causa Patent Ductus Arteriosus, comorbid with suspected lung tuberculosis and chronic disease

anaemia. The patient was then treated in the children's ward. The initial management carried out was in the form of non-pharmacological and pharmacological



management. Non-pharmacological management is in bed rest in a semi-fowler position, a diet low in salt and sufficient protein. The pharmacological treatment given was D5 intravenous mixed ¼ normal saline of 300 cc/ 24 hours, ceftriaxone injection 20 mg/12 hours, nasal oxygen 3 L/minutes, furosemide injection 20 mg/12 hours, captopril 12.5 mg/ 12 hours, VIP albumin. 1 capsule/ 6 hours.

Following up on the first day of treatment, the patient still felt tight and coughed—complaints of swelling in the abdomen and legs were reduced. There is a continuous murmur on heart examination. On abdominal ultrasound examination, there are signs of congestive liver disease and hepatic cirrhosis. Pharmacological management was continued. On the fifth day of hospitalization, the sputum examination result showed negative acid-resistant bacilli, so that the suspicion of pulmonary tuberculosis could be ruled out. Complaint of shortness of breath, swollen legs and stomach have decreased. Non-pharmacological and pharmacological management is continued.

3. Discussion

This congenital heart disease problem can lead to complications to other problems, one of which is heart failure. Management of the management of heart failure in CHD sufferers is a challenge because the onset of heart failure is unknown depending on the severity of the CHD and the treatment the patient has done. According to the Heart Failure Society of America, heart failure is a pulmonary system syndrome and systemic venous congestion and inadequate peripheral oxygen distribution, at rest or activity, caused by cardiac dysfunction.^{5,6}

The prevalence of congenital heart disease (CHD) is reported to be found in 10 out of 1000 live births, and the incidence is between 3-20 per 1000 live births. CHD is not found at birth alone and is found mostly in adolescent and adult patients. More than a quarter of CHD findings are diagnosed past infancy.³ The number of successful survival rates for CHD sufferers has increased dramatically in recent decades. The survival

rate for newborns with complex CHD is around 90%. The more CHD sufferers who survive, the more patients are at risk of suffering from heart failure. Despite success in drug therapy or surgery, patients in the long term still often experience the effects of heart, lung, or hepatic system abnormalities caused by sequelae of cardiac dysfunction.⁷

Continued heart failure can lead to complications to other systems, one of which is the hepatic system. Heart failure results in venous congestion in the portal vein so that the portal vein pressure increases, which is called portal hypertension. Portal hypertension causes fluid to pass through the walls of blood vessels and into the tissues. Typical examples are ascites and pitting oedema. Another cause of portal hypertension is the destruction of hepatocytes in the liver. There are stellate cells in the liver between the hepatocyte and sinusoid cells or what is called the perisinusoidal space. These cells are quiescent or inactive conditions, but they can function as a reserve of vitamin A. In damaged hepatocytes, stellate cells will be activated, which will then produce TGF-β and collagen protein. These will accumulate and make the perisinusoidal space enlarge, then compress the sinusoids, causing portal hypertension. One of the functions of the liver is producing albumin. If there is liver damage, hypoalbuminemia must be distinguished from hypoalbuminemia due to liver damage or kidney damage resulting in proteinuria. In addition, patients may appear jaundiced due to decreased conjugate function of bilirubin.^{8,9}

Activity intolerance is common and essential in the diagnosis of heart failure. Activity intolerance is the leading cause of morbidity and reduces the quality of life of people with CHD. However, in children, limitations in activities are sometimes difficult to assess. In older patients, it can be measured using a more objective diagnostic test tool, namely cardiopulmonary exercise testing using a treadmill or cycle ergometer, which is adjusted to the level of activity limitations in CHD sufferers. The assessed peak oxygen consumption (VO₂), pulse rate, blood pressure, oxygen



saturation, and ventilation response.¹⁰

In this patient, the diagnosis of heart failure was made from the history and physical examination results, namely shortness of breath accompanied by an enlarged abdomen and legs due to extracellular fluid retention. The tightness experienced by the patient is a tightness that worsens with an activity that can be suspected due to enlargement of the heart organ. Physical examination found was cardiomegaly signs on the chest examination, jugular vein distension, and pitting oedema in both legs. The diagnosis is confirmed by ECG and chest x-ray, which shows the impression of massive cardiomegaly. Congenital heart disease in patients has not been confirmed with certainty about CHD's type because it can only be seen from the clinical congestion. However, it was found that a continuous murmur on auscultation of the heart led to a type of Patent Ductus Arteriosus CHD. Further tests such as echocardiography or cardiac catheterization are required. Chronic disease anaemia is obtained from clinical patients, namely pale, anaemic, and complete blood count results leading to anaemia. This anaemia is also supported by chronic diseases suffered by patients, namely CHD and chronic heart failure. However, other tests are needed to make this diagnosis, namely, peripheral blood morphology. Cardiac cirrhosis is enforced from clinical patients such as jaundice, hepatomegaly, ascites, and pitting oedema due to hepatic congestion caused by vena cava congestion due to abnormalities in the heart. This diagnosis is also supported by ultrasound results which show congestion in the liver.^{1,11}

The management of this patient is slightly different because the patient has complications in the liver. The liver plays a role in the absorption, distribution and elimination of most drugs. Drugs are converted in the liver by an enzymatic process to become active, inactive, or even toxic metabolites. Damage to the liver can alter the pharmacokinetics of a heart drug, which can result in toxicity. Therefore a dose adjustment is required in this case. However, there are no standard regulations regarding drug dose modification in heart

failure patients with hepatic dysfunction.¹¹ The use of ACE inhibitors and loop diuretics is considered because these two agents do not aggravate liver damage. ACE inhibitors are first-line therapy in the treatment of heart failure. These drugs increase cardiac output and decrease left ventricular filling pressure due to vasodilating effects. In the presence of hepatic dysfunction, a decrease in prodrug transformation and inactivation of the active drug can occur. Loop diuretics such as furosemide are used for body fluid management in people with heart failure because of their natriuretic effect compared to other diuretic types. Loop diuretics are metabolized mostly in the liver.⁹⁻¹¹

4. Conclusion

Management of decompensated heart failure accompanied by cardiac cirrhosis includes pharmacological management that does not aggravate the liver, namely ACE inhibitors and loop diuretic agents. Besides, non-pharmacological management such as resting position and a diet sufficient in protein and low salt help improve the patient's general condition.

5. References

1. Wahab AS. Patent Ductus Arteriosus. In: Wahab AS. Children Cardiology: Non Sianotic Congenital Heart Disease. 1st ed. Jakarta: EGC. 2006; 69-76.
2. Sudoyo AW, Setiyohadi B, Alwi I, Simadibrata KM, Setiati S. Internal Medicine: Faculty of Medicine Universitas Indonesia. 4th ed. Jakarta: EGC. 2007; 1641-46.
3. Stout, et al. Chronic heart failure in congenital heart disease: A scientific statement from the American heart association. 2016. Accessed on: <http://ahajournals.org>
4. Guyton AC, Hall JE. Medical Physiology. 11th ed. Jakarta: EGC. 2007; 353- 56.
5. Snell RS. Clinical Anatomy. 4th ed. Jakarta: EGC. 2006; 108-141.
6. Desantis ERH, Clyman RI. Patent Ductus



Arteriosus: Pathophysiology and Management
Patent Ductus Arteriosus. Journal of
Perinatology. 2006; 1(2):14-18.

7. Schneider DJ, Moore JW. Patent Ductus Arteriosus. University of Illinois College of Medicine at Peoria and Cardiac Catheterization Laboratory, Children's Hospital of Illinois, Peoria, Ill (DJS). 2006; 114.
8. Ontoseno T. Diagnosis and management of critical congenital heart disease in neonates. cardiology division of pediatrics FK Unair - RSUP Dr. Soetomo Surabaya. 2003; a. 8-9.
9. Baraas F. Introduction to Heart Disease in Children. Indonesian Journal of Cardiology. 1994; 12(2): 80-5.
10. Mulyadi MD. Management of Congenital Heart Disease Without Difference. Ministry of Health of the Republic of Indonesia. 2007.
11. Alvarez AM, Mukherjee D. Liver abnormalities in cardiac disease and heart failure. Int J Angiol. 2011; 20:135– 142.

