JOURNAL OF ANESTHESIOLOGY AND CLINICAL RESEARCH
hmpublisher.com/index.php/jacr

e-ISSN 2745-9497
Open Access · Peer-reviewed

Journal of Anesthesiology and Clinical Research, Vol. 6, No. 2, 2025, pp. 321–331

CASE REPORT

Ultrasound-Guided Dual Plexus Blockade with Light Dexmedetomidine Sedation for Clavicle Fixation after Decompressive Craniectomy: An Observational Analytic Case Study

Muhammad Husni Thamrin[1], Bara Adithya[1], Muhammad Dony Hermawan[1*]

[1] Department of Anesthesiology and Intensive Therapy, Faculty of Medicine, Universitas Sebelas Maret, Surakarta, Indonesia

ARTICLE INFO

Article history
Received: August 20, 2025
Revised: September 18, 2025
Accepted: October 16, 2025
Available online: October 27, 2025
Published: October 29, 2025

Keywords
Decompressive craniectomy
Dual plexus blockade
Interscalene block
Neuroanesthesia
Superficial cervical plexus block
Traumatic brain injury

DOI
https://doi.org/10.37275/jacr.v6i2.994

Corresponding author
Muhammad Dony Hermawan
donyeyeshield@gmail.com

ABSTRACT

Background. Non-neurosurgical surgery soon after traumatic brain injury (TBI) and decompressive craniectomy risks secondary brain injury. Few reports describe regional anesthesia as the primary technique in this setting.

Objective. To describe the anesthetic management and hemodynamic course of a patient who had clavicle fixation under ultrasound-guided interscalene and superficial cervical plexus blocks with dexmedetomidine sedation after craniectomy.

Methods. This CARE-guided report describes a 24-year-old man (ASA physical status III-E) who needed fixation of a displaced mid-shaft clavicle fracture six days after craniectomy for a 70 mL epidural hematoma. He received an interscalene block (15 mL) and a superficial cervical plexus block (10 mL) of 0.375% levobupivacaine, and dexmedetomidine 0.4 µg/kg/hr without a bolus. Arterial pressure and heart rate were recorded at 11 time points. Cerebral perfusion pressure (CPP) was estimated as mean arterial pressure (MAP) minus an assumed intracranial pressure of 10–12 mmHg.

Results. Surgery lasted 150 minutes without airway instrumentation or vasoactive drugs. MAP ranged from 83.3 to 93.3 mmHg (lowest 83.3 mmHg at skin closure, −10.7% from baseline) and estimated CPP from 73.3 to 81.3 mmHg. The rate-pressure product fell from 10,496 to 8,024–9,375 bpm·mmHg after the block. Diaphragmatic excursion exceeded 1.8 cm. No rescue opioid was needed. The patient was discharged on postoperative day 2 with a Glasgow Coma Scale score of 15.

Conclusion. The technique was feasible. Arterial pressure stayed stable. Intracranial pressure was not measured, and dexmedetomidine probably contributed, so the case cannot show neuroprotection; it supports prospective study.

Access licence: Open access. This article is distributed under the terms of the Creative Commons Attribution-NonCommercial-ShareAlike 4.0 International Licence (CC BY-NC-SA 4.0), which permits non-commercial use, sharing, adaptation and reproduction in any medium, provided the original author and source are credited and derivative works are licensed under identical terms.
Copyright: © 2025 The Author(s). Published by HM Publisher in collaboration with CMHC Research Center. e-ISSN 2745-9497.

1. Introduction

Traumatic brain injury (TBI) is among the leading causes of morbidity and mortality worldwide. An estimated 69 million people sustain a TBI each year.[1] Acute epidural hematoma is one of its deadliest lesions. It needs timely surgery, and decompressive craniectomy is used in selected patients to avert fatal brainstem herniation.[2] Decompression relieves life-threatening intracranial hypertension at once. Even so, the prognosis of survivors depends largely on preventing and treating secondary insults over the following hours and days.[3] Secondary injury involves blood-brain barrier disruption, oxidative stress with lipid peroxidation, excitotoxicity and inflammation. Systemic insults can make it worse: hypotension, hypoxemia, hypercarbia or surges in intracranial pressure (ICP).[3,4]

Polytrauma patients recovering from emergency neurosurgery often carry major skeletal injuries. Patients with TBI frequently sustain concomitant extracranial injuries.[5] The clavicle is among the most commonly broken bones. Its fractures account for up to 5% to 10% of fractures seen in hospital emergency admissions.[6] For displaced mid-shaft fractures, open reduction and internal fixation (ORIF) with plating is increasingly used because it lowers the risk of nonunion and symptomatic malunion.[7] Surgery outside the skull soon after TBI has been linked to worse functional and cognitive outcomes at one year, although the association was observed in patients who did not have intracranial surgery and does not prove causation.[8] After a large bone flap is removed, intracranial hypertension may persist or recur.[9,10] Cerebral autoregulation is also frequently disrupted after TBI.[11] Cerebral blood flow (CBF) then depends on cerebral perfusion pressure (CPP), defined as mean arterial pressure (MAP) minus ICP.[12] The Monro-Kellie doctrine describes the rigid cranial vault as holding brain tissue, blood and cerebrospinal fluid (CSF) of constant total volume.[13]

Clavicle fixation is commonly performed under general endotracheal anesthesia (GA).[14] In a patient with TBI, that choice matters. GA can compromise cerebral perfusion pressure, oxygenation and ventilation, so the technique

must be chosen to prevent secondary brain injury.[15] Induction with propofol or thiopental can cause hypotension and a fall in CPP.[15] Laryngoscopy, intubation and surgical stimulation provoke a sympathetic response, with rises in heart rate and blood pressure that may raise ICP and risk brain edema or intracranial hemorrhage.[16] Raised intrathoracic pressure during positive pressure ventilation may reduce the pressure gradient for cerebral venous outflow and raise ICP.[15] Coughing at emergence is associated with intracranial hypertension.[17] Volatile anesthetics add to the risk. At higher concentrations they dilate cerebral vessels and increase CBF and ICP.[15]

Ultrasound-guided regional anesthesia can provide site-specific surgical anesthesia in selected high-risk patients while avoiding general anesthesia and airway instrumentation.[18] The sensory supply of the clavicle overlaps. Cadaveric dissection shows contributions from the supraclavicular nerves of the superficial cervical plexus (C3–C4), the subclavian nerve and the lateral pectoral nerve.[19] An interscalene brachial plexus block (ISB) alone, or a superficial cervical plexus block (SCPB) alone, often fails to anesthetize the deep clavicular region completely.[20] Combined cervical and brachial plexus blocks can serve as the sole anesthetic for clavicle fracture surgery, although success rates of 60% to 80% were reported when ISB was paired with an SCPB.[21] Low-dose dexmedetomidine adds a sedative option. This highly selective alpha-2 adrenergic agonist produces arousable, sleep-like sedation without respiratory depression.[22]

Clinical evidence on regional anesthesia as the only technique for fracture surgery is limited and consists largely of case reports.[18] Most published work concerns elective orthopedic patients. Blocks are used mainly as adjuncts to general anesthesia for postoperative analgesia.[23] We found no report of ISB plus SCPB as the primary anesthetic after decompressive craniectomy; the closest published case combined the two blocks for clavicle fixation in a pregnant patient with TBI.[24] The objective of this report is to describe the anesthetic management and the hemodynamic course of that patient in numerical detail, with an estimate of cerebral perfusion pressure, and to discuss what one case can and cannot show.

2. Methods

2.1. Report design and reporting guideline

This is a single case report prepared according to the CARE (CAse REport) guideline.[26] The analysis is descriptive. No inferential hypothesis testing was performed, because such tests are not meaningful in a single patient.

2.2. Setting

The patient was managed by the Department of Anesthesiology and Intensive Therapy, Faculty of Medicine, Universitas Sebelas Maret, Surakarta, Indonesia.

2.3. Patient information and case selection

The patient was a 24-year-old man (body weight 70 kg, height 172 cm, body mass index 23.66 kg/m^2, American Society of Anesthesiologists [ASA] physical status III-E). After a high-speed motor vehicle collision he presented with a Glasgow Coma Scale (GCS) score of 9 (E2, V2, M5). Cranial computed tomography (CT) showed a right temporoparietal acute epidural hematoma (volume 70 mL, with 12 mm subfalcine midline shift and ipsilateral ventricular effacement). Right decompressive craniectomy with clot evacuation was completed within 2 hours of arrival. He was ventilated for 48 hours in the intensive care unit (ICU) and extubated on postoperative day 3. He also had a severely displaced, comminuted mid-shaft right clavicle fracture, for which open reduction and internal fixation was scheduled exactly six days after craniectomy.

2.4. Case timeline

Table 1 sets out the chronology in relative time, from the trauma (day 0) to discharge.

Table 1. Case timeline in relative time: events, investigations and interventions from trauma to discharge.

Time point	Clinical event	Investigation and result	Intervention
Day 0	High-speed motor vehicle collision; GCS 9 (E2, V2, M5)	Cranial CT: right temporoparietal acute epidural hematoma, 70 mL, midline shift 12 mm, ipsilateral ventricular effacement; displaced mid-shaft right clavicle fracture	Right decompressive craniectomy and clot evacuation within 2 hours of arrival
Day 0 to day 2	Neurocritical care	48 hours of ventilation in the ICU	Neuroprotective sedation, $PaCO_2$ titration, controlled ventilation
Day 3	Tracheal extubation	Stable respiratory mechanics, normal airway reflexes	—
Day 6, before surgery	GCS 15 (E4, V5, M6); pupils isocoric, 3 mm, brisk	Repeat CT: midline shift resolved, edema decreased, skull defect; laboratory values normal; Mallampati II	Standard monitors; arterial line
Day 6, T0–T10	Clavicle ORIF, 150 minutes	MAP 83.3–93.3 mmHg; estimated CPP 73.3–81.3 mmHg (Table 3)	Dexmedetomidine from T2; interscalene and superficial cervical plexus blocks at T3
Day 6 to day 8 (48 hours)	GCS 15; NRS ≤ 1/10 at rest, ≤ 2/10 on movement	MAP 80–88 mmHg; no nausea or vomiting (Table 4)	Paracetamol 1 g IV and ibuprofen 400 mg every 8 hours; no rescue opioid
Day 8 (postoperative day 2)	Discharge home	GCS 15	Oral paracetamol

Notes: *CT: computed tomography; ICU: intensive care unit; GCS: Glasgow Coma Scale; IV: intravenous; MAP: mean arterial pressure; CPP: cerebral perfusion pressure; NRS: numeric rating scale; ORIF: open reduction and internal fixation. Day 0 is the day of trauma and craniectomy; surgery was on day 6.*

2.5. Clinical findings and diagnostic assessment

On the morning of surgery, cranial CT showed satisfactory decompression, complete hematoma clearance, no rebleeding and resolution of the midline shift, with residual focal post-traumatic parenchymal changes and a large osseous defect. Airway assessment gave a Mallampati class II view, a thyromental distance above 6 cm and full cervical spine mobility without focal pain. Hematological, renal and coagulation profiles were within normal limits. There was no diagnostic difficulty or delay.

2.6. Therapeutic intervention

Standard ASA monitoring (electrocardiography, pulse oximetry, non-invasive blood pressure and core temperature) was started in the operating theater. The patient lay semi-recumbent with the head of the bed raised 30°, which lowers ICP in patients with acute brain injury.[27] Under aseptic conditions and local infiltration anesthesia, a 20-gauge radial arterial catheter was placed in the left wrist (contralateral to the fracture) for continuous invasive pressure monitoring. Dexmedetomidine was infused at 0.4 µg/kg/hr without a bolus to reach a Ramsay Sedation Scale score of 2–3 (calm, tranquil, easily rousable and cooperative) with unassisted spontaneous ventilation.

Both blocks were done under sterile conditions with a high-frequency linear array transducer (12–5 MHz, Sonosite Edge II) in a sterile sheath. For the interscalene block, the probe lay in the transverse axial plane at the level of the cricoid cartilage (C6). The C5, C6 and C7 roots appeared as round hypoechoic nodules in the typical traffic-light array between the anterior and middle scalene muscles. After a lidocaine skin wheal, a 22-gauge, 50-mm echogenic insulated needle (Stimuplex Ultra 360, B. Braun) was advanced in-plane from lateral to medial into the groove next to the C5–C6 roots. Blood aspiration was negative. Under direct dynamic visualization, 15 mL of 0.375% levobupivacaine was injected, and circumferential perineural spread was seen. For the superficial cervical plexus block, the transducer was moved over the posterior border of the sternocleidomastoid muscle (SCM) at its midpoint (Erb point). The needle was directed in-plane from posterior to anterior, with its tip deep to the investing cervical fascia along the posterior border of the SCM. Aspiration was negative, and 10 mL of 0.375% levobupivacaine was deposited in increments, with laminar fascial spread around the branches of the supraclavicular nerves. The total dose was 93.75 mg (1.34 mg/kg).

The time points were T0 (baseline in the operating room), T1 (after arterial line placement), T2 (dexmedetomidine initiation), T3 (after block placement), T4 (skin incision), T5 (periosteal stripping), T6 (fracture reduction and clamping), T7 (plate fixation), T8 (myofascial closure), T9 (skin suture completion) and T10 (post-procedure recovery).

2.7. Outcome measures and follow-up

Sensory block density was tested at 25 minutes by thermal discrimination (cold alcohol swab) and motor block by shoulder abduction (deltoid, C5–C6), elbow flexion (biceps, C5–C6) and wrist extension (C6–C7). Diaphragmatic excursion was measured by ultrasound at the zone of apposition. The hemodynamic outcomes were mean arterial pressure (MAP = DBP + [SBP − DBP]/3, where SBP and DBP are systolic and diastolic blood pressure) and the rate-pressure product (RPP = heart rate [HR] × SBP, which reflects myocardial oxygen consumption). CPP was estimated as MAP minus an assumed ICP of 10–12 mmHg, taken from clinical and CT stability; ICP was not measured. Percentage changes were Δ% = [(Tn − T0) / T0] × 100%. After surgery, GCS, pupils, numeric rating scale (NRS) pain scores, rescue opioid use and MAP were recorded for 48 hours.

2.8. Ethics and consent

The study followed the Declaration of Helsinki (revised 2013). The CMHC Research Center Ethics Committee, Indonesia, gave approval (protocol number 2025/4108). The patient gave written informed consent after counseling on the anesthetic options, the technique and its possible complications (block failure, local anesthetic systemic toxicity, vascular puncture, pneumothorax and transient phrenic nerve palsy), and consent covered publication of de-identified clinical, hemodynamic and radiographic data.

3. Results

3.1. Presentation and baseline findings

On the day of surgery (post-craniectomy day 6) the patient had a GCS score of 15 (E4, V5, M6), was oriented and had brisk, isocoric pupillary light reflexes (3 mm). Baseline invasive vital signs showed normotension: SBP 128 mmHg, DBP 76 mmHg, MAP 93.3 mmHg, HR 82 beats/min, respiratory rate 16 breaths/min and SpO_2 98% on room air. Hemoglobin was 13.8 g/dL, hematocrit 41.2% and platelet count 248 × 10^9/L. Prothrombin time was 11.8 seconds (INR 1.02), serum sodium 140 mEq/L and serum creatinine 0.88 mg/dL. Table 2 lists the demographics, trauma history, imaging, vital signs and laboratory values.

Table 2. Baseline demographics, trauma history, clinical findings, preoperative vital signs, laboratory profile and cranial CT.

Domain	Parameter	Finding	Reference interval	Comment
Patient Demographics	Age & Chronological Category	24 years (Adult male)	N/A	Young adult with favorable physiological baseline and robust cardiovascular reserve
Anthropometric Indices	Body Weight & Height	70 kg & 172 cm	N/A	Body surface area = 1.83 m^2; ideal pharmacodynamic distribution volume for local anesthetics
Anthropometric Indices	Body Mass Index (BMI)	23.66 kg/m^2	18.50–24.90 kg/m^2	Normal body mass index
Neurotrauma History	Primary Trauma Mechanism	High-speed motor vehicle collision	N/A	Severe acceleration-deceleration forces causing blunt intracranial and shoulder girdle trauma
Neurological Presentation	Initial Glasgow Coma Scale (GCS)	9 / 15 (E2, V2, M5)	15 / 15	Severe traumatic brain injury requiring emergent invasive neurosurgical life salvage
Emergency Cranial CT Scan	Primary Intracranial Pathology	Acute epidural hematoma (right temporoparietal)	Absent	Space-occupying hematoma with mass effect
Emergency Cranial CT Scan	Calculated Hematoma Volume	70 mL (70 cm^3)	< 30 mL	Critical mass effect exceeding Monro-Kellie intracranial compensatory compliance reserve
Emergency Cranial CT Scan	Subfalcine Midline Shift	12 mm to contralateral left side	< 5 mm	Severe intracranial brain shift with imminent transtentorial herniation risk
Emergency Cranial CT Scan	Ventricular Morphology	Effacement of ipsilateral lateral ventricle	Symmetrical / Patent	Substantial regional intracranial hypertension with hemispheric parenchymal distortion
Emergency Neurosurgery	Definitive Surgical Intervention	Right decompressive craniectomy & evacuation	N/A	Bone flap removal and complete clot evacuation completed within 2 hours of arrival
Neurocritical Care Trajectory	Invasive Mechanical Ventilation	48 hours in Intensive Care Unit (ICU)	N/A	Neuroprotective sedation, tight $PaCO_2$ titration, and controlled mechanical ventilation
Neurocritical Care Trajectory	Tracheal Extubation Milestone	Successful extubation on Postoperative Day 3	N/A	Stable respiratory mechanics, normal airway reflexes, and prompt emergence
Preoperative Orthopedic Survey	Secondary Skeletal Injury	Displaced mid-shaft right clavicle fracture	Intact	Shortened, comminuted fracture with tenting of overlying skin requiring surgical ORIF
Pre-anesthetic Evaluation (Day 6)	Preoperative Glasgow Coma Scale	15 / 15 (E4, V5, M6)	15 / 15	Complete restoration of neurological consciousness without focal sensorimotor deficit
Pre-anesthetic Evaluation (Day 6)	Repeat Cranial CT Imaging	Resolution of midline shift, decreased edema	Normal post-op	Favorable intracranial restitution; presence of skull defect rendering brain vulnerable
Airway Examination	Mallampati Classification & Cervical ROM	Class II view, thyromental distance > 6 cm	Class I–II	Normal airway anatomy without pain on gentle cervical manipulation
Preoperative Vital Signs	Systolic Blood Pressure (SBP)	128 mmHg	90–130 mmHg	Normotensive baseline; baseline perfusion pressure within the reference range
Preoperative Vital Signs	Diastolic Blood Pressure (DBP)	76 mmHg	60–85 mmHg	Normal peripheral vascular resistance and preserved ventricular relaxation
Preoperative Vital Signs	Mean Arterial Pressure (MAP)	93.3 mmHg	70–100 mmHg	Resting perfusion driving force safely above lower cerebral autoregulation threshold
Preoperative Vital Signs	Heart Rate & Cardiac Rhythm	82 beats/min, regular sinus rhythm	60–100 beats/min	Absence of tachyarrhythmia, Cushing triad response, or sympathoadrenal surge
Preoperative Vital Signs	Respiratory Rate & Oxygenation	16 breaths/min, SpO_2 98% on room air	12–20 bpm, > 95%	Adequate spontaneous oxygenation and unperturbed pulmonary gas exchange
Hematology & Coagulation	Hemoglobin & Hematocrit	13.8 g/dL & 41.2%	13.5–17.5 g/dL	Adequate oxygen carrying capacity to maintain cerebral oxygen delivery (CDO_2)
Hematology & Coagulation	Platelet Count	248 × 10^9/L	150–450 × 10^9/L	Normal primary hemostasis; no coagulopathy before the regional block
Hematology & Coagulation	Prothrombin Time & INR	11.8 sec & 1.02	11–14 sec & 0.8–1.2	Normal extrinsic pathway; no contraindication to deep fascial needle puncture
Biochemistry & Renal Function	Serum Creatinine & Blood Urea Nitrogen	0.88 mg/dL & 14.2 mg/dL	0.7–1.2 mg/dL	Preserved renal filtration ensuring normal local anesthetic and drug clearance
Biochemistry & Electrolytes	Serum Sodium & Potassium	140 mEq/L & 4.1 mEq/L	135–145 & 3.5–5.0	Eunatremic and eukalemic state preventing cytotoxic cerebral edema or arrhythmogenesis

Notes: *ASA: American Society of Anesthesiologists; BMI: body mass index; CDO_2: cerebral delivery of oxygen; CT: computed tomography; DBP: diastolic blood pressure; GCS: Glasgow Coma Scale; ICU: intensive care unit; INR: international normalized ratio; MAP: mean arterial pressure; ORIF: open reduction and internal fixation; SBP: systolic blood pressure; SpO_2: peripheral oxygen saturation; TBI: traumatic brain injury.*

3.2. Diagnostic findings

Repeat cranial CT confirmed satisfactory decompression without intracranial hemorrhage or residual subfalcine herniation (Table 2).

3.3. Treatment course and outcome

Complete sensory loss across C3–T1 and dense upper extremity motor block were recorded within 25 minutes of local anesthetic deposition. The operation lasted 150

minutes. Table 3 gives all 11 time points, which are plotted in Figure 1 (the anesthetic strategy is summarized in Figure 2) and Figure 3. During surgery SBP ranged from 118 to 126 mmHg, DBP from 66 to 74 mmHg and MAP from 83.3 to 91.3 mmHg; with the baseline value included, MAP ranged from 83.3 to 93.3 mmHg. Pressures began to fall before the blocks. At T2 (dexmedetomidine initiation, 20 minutes), MAP was 87.3 mmHg (Δ% = −6.4%), HR 74 beats/min (Δ% = −9.8%) and RPP 9,028 bpm·mmHg (Δ% = −14.0%). After block placement (T3), MAP was 85.3 mmHg (Δ% = −8.6%). At skin incision (T4), periosteal stripping (T5) and fracture reduction (T6), MAP held at 89.3–90.3 mmHg (Δ% = −4.3% to −3.2%). The lowest MAP, 83.3 mmHg (Δ% = −10.7%), was recorded at skin closure (T9). No episode of MAP below 80 mmHg or above 95 mmHg occurred.

Table 3. Intraoperative time points: invasive hemodynamics, estimated cerebral perfusion pressure and rate-pressure product at 11 time points.

Time point	Min	SBP	DBP	MAP	HR	Assumed ICP	Est. CPP	RPP	MAP Δ%	CPP Δ%	Clinical and interventional events
Baseline in Operating Room (T_0)	0	128	76	93.3	82	12	81.3	10,496	0.0%	0.0%	Standard monitors applied, 30° head-up tilt, awake and calm
Post-Arterial Line Placement (T_1)	10	126	74	91.3	80	12	79.3	10,080	-2.1%	-2.5%	Radial line cannulation under local infiltration, minimal discomfort
Dexmedetomidine Initiation (T_2)	20	122	70	87.3	74	11	76.3	9,028	-6.4%	-6.2%	0.4 µg/kg/hr infusion started, smooth onset of cooperative sedation
Post-Dual Plexus Block Placement (T_3)	45	120	68	85.3	70	11	74.3	8,400	-8.6%	-8.6%	ISB (15 mL) + SCPB (10 mL) 0.375% levobupivacaine; Ramsay score 2–3
Surgical Skin Incision (T_4)	60	124	72	89.3	71	11	78.3	8,804	-4.3%	-3.7%	Incision along clavicular shaft; sensory block present; no hemodynamic spike
Periosteal Stripping & Exposure (T_5)	85	125	73	90.3	74	12	78.3	9,250	-3.2%	-3.7%	Subperiosteal dissection; no response to stimulation
Fracture Reduction & Clamping (T_6)	110	125	73	90.3	75	12	78.3	9,375	-3.2%	-3.7%	Bone fragment reduction with reduction forceps; no motor movement
Dynamic Compression Plate Fixation (T_7)	135	123	71	88.3	73	11	77.3	8,979	-5.4%	-4.9%	Seven-hole anatomical locking plate and screw fixation, stable vitals
Myofascial Layer Closure (T_8)	160	121	69	86.3	71	11	75.3	8,591	-7.5%	-7.4%	Deep fascial and platysma re-approximation, minimal blood loss (75 mL)
Subcuticular Skin Suture Completion (T_9)	180	118	66	83.3	68	10	73.3	8,024	-10.7%	-9.8%	Sterile dressing placed; total surgery time 150 min, dexmed. ceased
Post-Procedure Recovery / Ward Transfer (T_{10})	200	120	70	86.7	72	10	76.7	8,640	-7.1%	-5.7%	Alert, GCS 15, NRS pain 0/10, no PONV, direct transfer to ward

Notes: *Units: elapsed time in minutes (Min); SBP, DBP, MAP, ICP and CPP in mmHg; HR in beats/min; RPP in bpm·mmHg; Δ% versus T0 (baseline). CPP: estimated cerebral perfusion pressure (MAP − assumed ICP; ICP was not measured); DBP: diastolic blood pressure; HR: heart rate; ICP: intracranial pressure; ISB: interscalene brachial plexus block; MAP: mean arterial pressure; RPP: rate-pressure product (HR × SBP); SBP: systolic blood pressure; SCPB: superficial cervical plexus block; Δ%: percentage change versus baseline, [(Tn − T0) / T0] × 100%; T0–T10: time points defined in Section 2.6.*

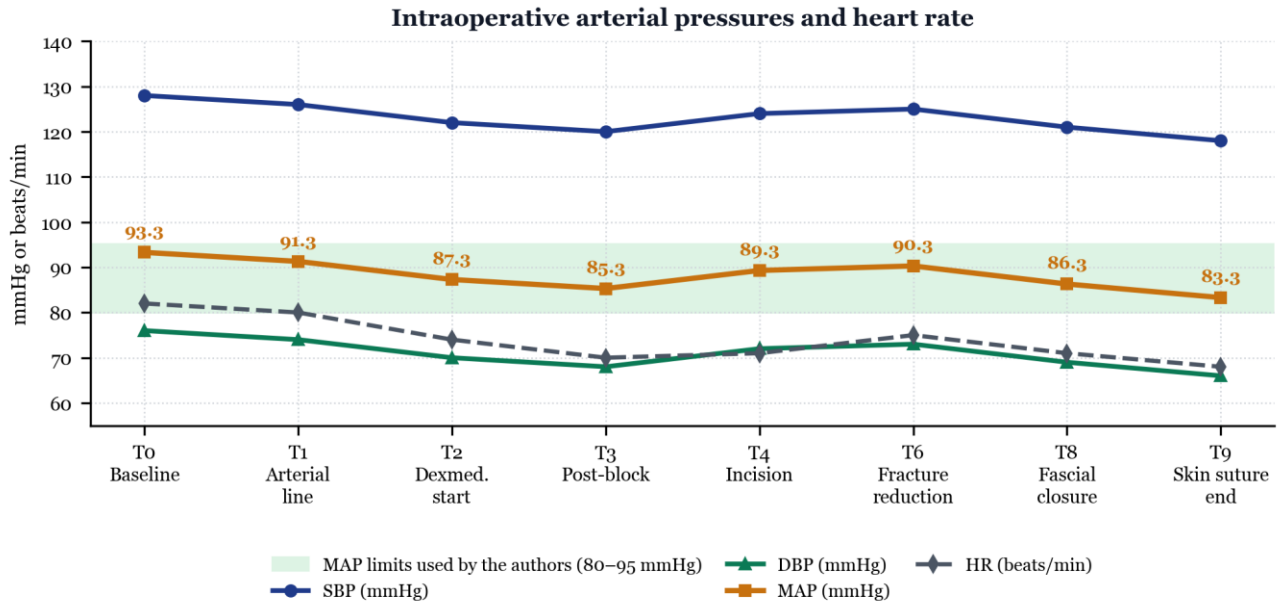

Figure 1. Arterial pressures and heart rate at eight time points (T0–T4, T6, T8 and T9; values from Table 3). The shaded band marks the 80–95 mmHg limits for MAP used by the authors. MAP was lowest at skin closure (T9, 83.3 mmHg).

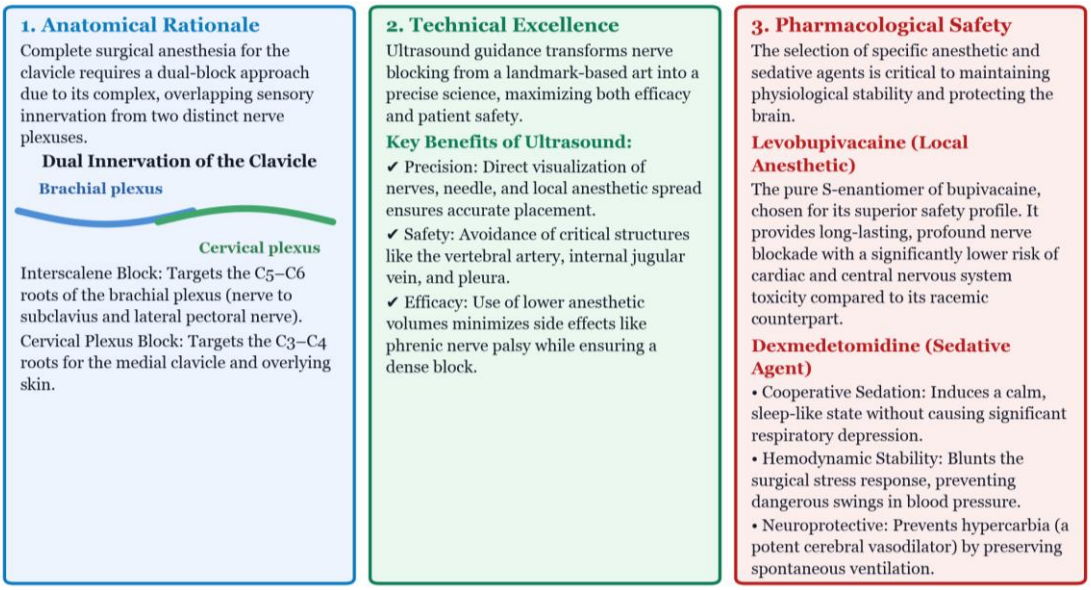

Figure 2. Schematic summary of the anatomical, technical and pharmacological rationale of the anesthetic strategy. The drawing is conceptual and not to scale.

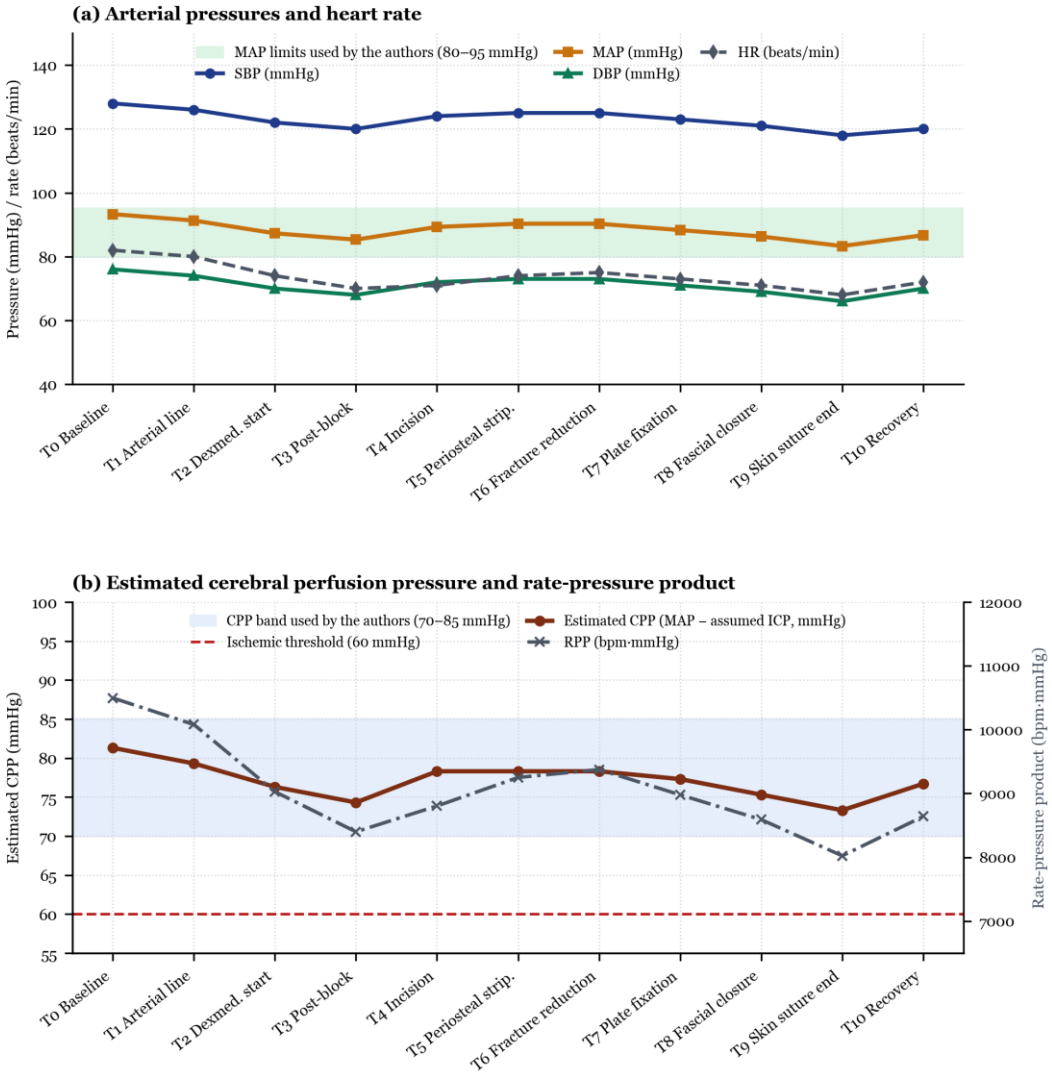

Figure 3. Trajectory over the 11 time points. (a) SBP, DBP, MAP and HR, with the 80–95 mmHg MAP limits used by the authors. (b) Estimated CPP (MAP minus an assumed ICP of 10–12 mmHg) and rate-pressure product (RPP).

Estimated CPP stayed between 73.3 and 81.3 mmHg throughout the repair (Figure 3), above the ischemic threshold of 60 mmHg. Because ICP was assumed rather than measured, this range follows the MAP. Heart rate fell from 82 beats/min at baseline to 70 beats/min at T3 (Δ% = −14.6%), stayed between 71 and 75 beats/min during

fixation and was 68 beats/min at closure (T9, Δ% = −17.1%). The RPP fell from 10,496 bpm·mmHg at baseline to 8,400 bpm·mmHg at T3 (Δ% = −20.0%) and stayed below 9,400 bpm·mmHg during reduction and plating (T6: 9,375 bpm·mmHg). Its lowest value was 8,024 bpm·mmHg at T9 (Δ% = −23.6%). Figure 4 shows the percentage changes from baseline. The largest change in MAP was 10.7%.

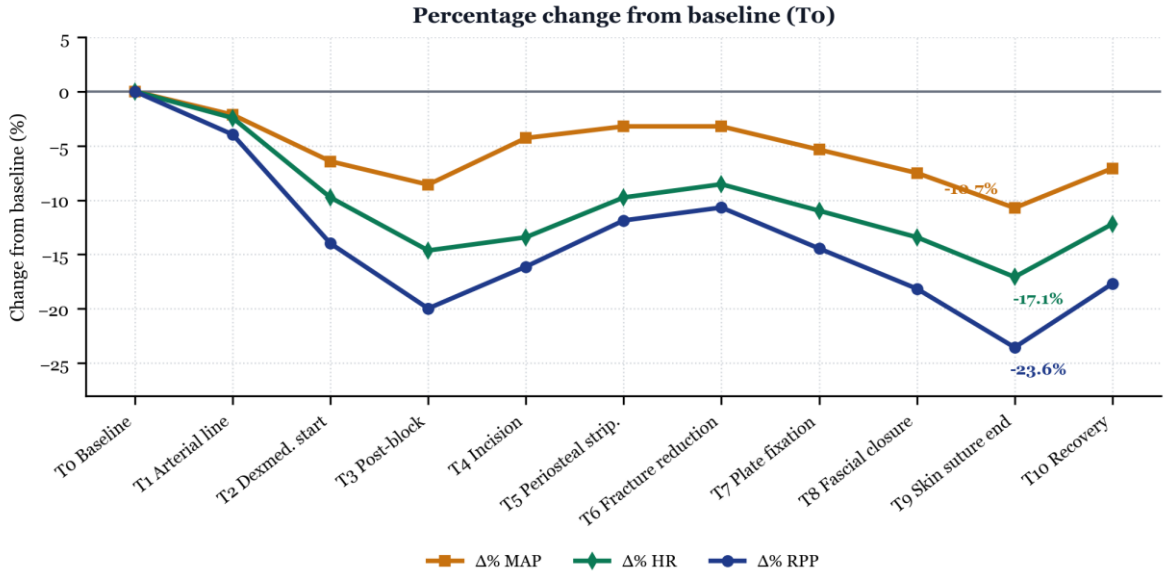

Figure 4. Percentage change from baseline (T0) of MAP, HR and RPP at each time point. At T9 the changes were −10.7% (MAP), −17.1% (HR) and −23.6% (RPP).

Ventilation stayed spontaneous and unlabored, with a respiratory rate of 14–16 breaths/min and SpO_2 of 98–100% on 2 L/min nasal cannula oxygen. The dexmedetomidine infusion kept the Ramsay Sedation Scale at 2–3 with no airway obstruction, apnea or desaturation. Blood loss was approximately 75 mL, and 1,000 mL of lactated Ringer's solution was infused. Post-procedure ultrasound showed symmetrical bilateral diaphragmatic excursions above 1.8 cm and no phrenic nerve palsy. No local anesthetic systemic toxicity (LAST), arrhythmia or Horner syndrome occurred.

Table 4 gives the 48-hour postoperative course. At the end of the procedure the patient was awake and oriented (GCS 15) and reported no pain (NRS 0/10). There was no sedative hangover, so the post-anesthesia care unit (PACU) was bypassed and he went directly to the orthopedic ward. Sensory and motor block lasted 14 hours after surgery. Oral fluids began at hour 2, and assisted mobilization started at hour 12. Pain scores stayed low (resting NRS ≤ 1/10, dynamic NRS ≤ 2/10) on scheduled intravenous paracetamol (1 g every 8 hours) and oral ibuprofen (400 mg every 8 hours). No rescue opioid was needed during the 48-hour stay, and there were no episodes of postoperative nausea and vomiting (PONV). The patient was discharged home on postoperative day 2.

Table 4. Postoperative course over 48 hours: neurological status, pain scores, rescue opioid use and mean arterial pressure.

Timeline	GCS (E/V/M)	Pupils	Resting NRS (0–10)	Dynamic NRS (0–10)	Rescue opioid (mg)	MAP range (mmHg)	Clinical and neurological milestones
Immediate Post-Op (Hour 0)	15 (E4 V5 M6)	Isocoric 3 mm, brisk	0 / 10	0 / 10	0 mg	84–88	Bypassed PACU directly to orthopedic ward; alert, cooperative, comfortable
Postoperative Hour 4	15 (E4 V5 M6)	Isocoric 3 mm, brisk	0 / 10	0 / 10	0 mg	82–88	Normal oral fluid intake tolerated; dense motor and sensory block persisting
Postoperative Hour 8	15 (E4 V5 M6)	Isocoric 3 mm, brisk	0 / 10	1 / 10	0 mg	80–86	Initial gradual motor recovery in hand intrinsics; surgical site pain-free
Postoperative Hour 12	15 (E4 V5 M6)	Isocoric 3 mm, brisk	1 / 10	2 / 10	0 mg	82–86	Block resolving smoothly; scheduled paracetamol (1 g IV) administered
Postoperative Hour 18	15 (E4 V5 M6)	Isocoric 3 mm, brisk	1 / 10	2 / 10	0 mg	80–84	Comfortable, full sensory regression; scheduled oral ibuprofen (400 mg) started
Postoperative Hour 24	15 (E4 V5 M6)	Isocoric 3 mm, brisk	1 / 10	2 / 10	0 mg	82–88	Assisted out-of-bed ambulation achieved; zero nausea, zero vomiting
Postoperative Hour 36	15 (E4 V5 M6)	Isocoric 3 mm, brisk	0 / 10	1 / 10	0 mg	80–86	Independent ward ambulation; clean surgical and craniectomy wounds
Postoperative Hour 48 (Discharge)	15 (E4 V5 M6)	Isocoric 3 mm, brisk	0 / 10	1 / 10	0 mg	82–86	Full independent mobilization; discharged home with oral paracetamol

Notes: *GCS: Glasgow Coma Scale; MAP: mean arterial pressure; NRS: numeric rating scale (0 = no pain, 10 = worst imaginable pain); PACU: post-anesthesia care unit.*

4. Discussion

4.1. Principal lesson of the case

In this patient, ultrasound-guided interscalene and superficial cervical plexus blocks with light dexmedetomidine sedation allowed clavicle fixation six days after decompressive craniectomy. The airway was never instrumented, and arterial pressure stayed between 83.3 and 93.3 mmHg. The approach looks feasible in this setting. Whether it protects the brain is a different question, and one case cannot answer it.

4.2. Comparison with the published literature

Published reports of regional anesthesia for clavicle surgery in neurological or other high-risk patients are few (Table 5). The closest is a pregnant patient with TBI and an acute subdural hemorrhage. She had clavicle fixation under the same two blocks, without systemic opioids or sedatives, and her maternal hemodynamics stayed stable.[24] Other single cases used regional techniques instead of GA in a pregnant patient,[28] in a man with COVID-19,[29] and in a man with uncontrolled hypertension and a prior stroke.[30] A case of Steinert disease combined low-volume blocks with propofol under a laryngeal mask.[31] A series of 20 patients used low-volume C5 root and supraclavicular nerve blocks for awake clavicle surgery.[32] In a randomized trial of 120 patients, none needed conversion to GA, with ISB alone or with an added SCPB.[14] A trial of 70 patients under GA found that adding ISB to SCPB did not change opioid use but increased phrenic nerve palsy.[33] Our case differs from these in three ways: the recent craniectomy, the arterial line record and the dexmedetomidine infusion. The comparison remains at case level, because none of these reports measured ICP and none had a matched comparison group.

Table 5. Published reports of regional anesthesia for clavicle surgery compared with the present case.

Report	Design and patient	Technique	Main findings	Relevance to this case
Present case, 2025	Case report; 24-year-old man, day 6 after craniectomy, clavicle ORIF	ISB 15 mL + SCPB 10 mL, 0.375% levobupivacaine; dexmedetomidine 0.4 µg/kg/hr; spontaneous breathing	MAP 83.3–93.3 mmHg; estimated CPP 73.3–81.3 mmHg; no rescue opioid; PACU bypassed; discharge on day 2	—
Wibowo et al., 2025[24]	Case report with review; pregnant woman, 28 weeks, TBI with acute subdural hemorrhage, clavicle fracture	Single-shot ISB + SCPB; no systemic opioids or sedatives	Stable maternal hemodynamics, reassuring fetal tracing, opioid-sparing analgesia	Closest analogue; no craniectomy, no sedation
Okumus et al., 2025[28]	Case report with review; pregnant woman, 32 weeks, clavicle fracture	ISB + selective supraclavicular nerve block through one entry point	Surgery completed; no additional analgesics; no maternal or fetal complications	Regional-only fixation; no brain injury
Khadka et al., 2022[29]	Case report; 42-year-old man with COVID-19, clavicle ORIF	ISB + SCPB as the anesthetic	Fixation completed under regional anesthesia, avoiding airway instrumentation	Same block combination
Kuntoadi et al., 2025[30]	Case report; 68-year-old man, uncontrolled hypertension and prior stroke, clavicle fracture surgery	Peripheral nerve block instead of GA	Stable course, no complications	Cerebrovascular risk; no craniectomy
Pinto et al., 2019[31]	Case report; 53-year-old man with Steinert disease, clavicle fracture	Superior trunk block (1 mL 0.75% ropivacaine) + supraclavicular nerve blocks, with propofol infusion under a laryngeal mask	Pain-free, no opioid, ICU discharge at 24 hours	Low volume; airway device used
Diwan et al., 2020[32]	Case series; 20 patients with clavicle fractures, awake	C5 root block (3 mL 0.5% bupivacaine) + supraclavicular nerve block (3 mL)	Reliable anesthesia and analgesia without GA	Low-volume alternative
Mosaffa et al., 2024[14]	Randomized trial; 120 patients, ISB with or without SCPB	Regional anesthesia as the anesthetic	No conversion to GA; sedation, pain scores and meperidine use did not differ	ISB alone sufficed
Abdelghany et al., 2021[33]	Randomized trial; 70 patients under GA, SCPB with or without ISB	SCPB alone versus SCPB + ISB	Similar morphine use and pain; fewer phrenic palsies with SCPB alone (P = 0.03)	Phrenic trade-off of ISB; blocks given with GA

Notes: *ISB: interscalene brachial plexus block; SCPB: superficial cervical plexus block; GA: general anesthesia; ICU: intensive care unit; MAP: mean arterial pressure; CPP: cerebral perfusion pressure; PACU: post-anesthesia care unit; TBI: traumatic brain injury. Findings are those reported in the abstracts of the cited articles.*

Regional techniques have been used for clavicle surgery with success rates below 100%, and clavicle fixation is still mostly done under GA.[21,23] In one retrospective cohort, blocks were mainly an adjunct to GA and lowered pain scores and opioid use.[23] Our case adds a numerical record of arterial pressure, heart rate and rate-pressure product in a patient with a skull defect.

4.3. Pathophysiological or mechanistic interpretation

Secondary injury after severe TBI includes mitochondrial damage and lipid oxidation, processes that evolve over hours to days and so offer a window for intervention.[34] Outcome is related to the burden of secondary insults. Raised ICP, low CPP and impaired pressure reactivity are examples.[35] Under the classical Monro-Kellie doctrine, the cranial cavity is a rigid container of brain tissue, blood and CSF.[36] The doctrine has been challenged.[13,36] In the uninjured brain, shifts of CSF and venous blood out of the cranium buffer small volume changes. Edema, mass lesions and swelling use up this reserve and steepen the intracranial pressure-volume curve.[37] Craniectomy reduces the risk of herniation, but intracranial hypertension still occurred in 36% of patients after primary decompressive craniectomy for head trauma.[10] The driving pressure for cerebral blood flow is CPP = MAP – ICP.[15] Autoregulation keeps cerebral blood flow relatively constant across a wide range of MAP, and it is frequently disrupted after TBI.[11] When it fails, flow follows pressure. A fall in MAP then lowers CPP below the ischemic threshold (60 mmHg) and may cause focal hypoperfusion. A hypertensive surge may transmit excess pressure to damaged capillaries and favor edema or hemorrhage. In this patient CPP was not measured, and the estimate rests on an assumed ICP. Figure 5 summarizes the cascade conceptually for the regional approach and for conventional general anesthesia.



Figure 5. Conceptual cascade comparing the regional strategy with conventional general anesthesia in the post-craniectomy brain.

General anesthesia has several effects that matter here. Anesthesia in patients with recent head injury is demanding, and regional techniques may be preferable because of the limitations of GA.[38] Propofol and thiopental can cause hypotension and lower CPP.[15] Intubation provokes pressor responses that may raise ICP, and raised intrathoracic pressure may impede cerebral venous outflow.[15,16] Volatile agents can raise CBF and ICP at higher concentrations.[15] The strategy used here avoided airway instrumentation, positive pressure ventilation and volatile agents. It did not remove every hazard. Sedation, phrenic nerve palsy, vascular puncture and local anesthetic toxicity remain possible with the blocks.

Ultrasound guidance allows nerves and surrounding structures to be seen in real time. It permits much lower volumes of local anesthetic, with less aberrant spread than landmark techniques.[39] The clavicle is supplied by the supraclavicular, subclavian and lateral pectoral nerves,[19] so a cervical block combined with a brachial plexus block is a logical way to cover the operative field (Figure 2). Here the combination gave surgical anesthesia that held through periosteal stripping, fracture reduction and plate fixation without supplemental systemic analgesics, and real-time imaging helps to avoid the vertebral artery, the internal jugular vein and the transverse cervical vessels. Hemidiaphragmatic paralysis after interscalene block depends on volume: it was about twice as frequent with 20 mL as with 5 mL in one imaging study.[39] Low-volume interscalene injections still blocked the phrenic nerve in 88.9% of patients in one trial.[40] Our patient had 15 mL of 0.375% levobupivacaine, and diaphragmatic excursion was above 1.8 cm when it was measured after the block. Levobupivacaine, the S(−) enantiomer of bupivacaine, was chosen for its wider cardiac and neurovascular safety margin than the racemic mixture.

Dexmedetomidine was infused at a low dose (0.4 μg/kg/hr without a loading bolus). Unlike sedatives that act on the gamma-aminobutyric acid system, it produces sedation from which patients are easily aroused and which spares respiratory drive.[22] The patient therefore stayed cooperative and breathed spontaneously. A review reported neuroprotective properties of dexmedetomidine in brain injury, including TBI and craniotomy.[41] The drug has a high selectivity for alpha-2 over alpha-1 receptors (1620:1) and acts on the locus coeruleus to produce a state close to natural sleep.[42] It also lowers ICP through reduced CBF and cerebral metabolic rate.[38] That may have contributed to the pressure and heart rate decline,

together with a sympatholytic effect that may have blunted catecholamine surges during surgery (heart rate 68–75 beats/min, MAP 83.3–90.3 mmHg). The values began to fall at T1 and T2, before the blocks were placed. The blocks alone cannot be credited. The 10.7% fall in MAP and the 23.6% fall in RPP at skin closure may reflect sedation, calm and the passage of time as much as the blocks.

4.4. Implications for practice

The postoperative course was uneventful. The block lasted 14 hours, and no systemic opioid was needed. Serial GCS assessment was not confounded by sedative or opioid effects. No nausea or vomiting occurred, the PACU was bypassed, and the patient was discharged on postoperative day 2. These observations come from one patient without a comparator. They do not show that the technique reduces PONV, opioid use or hospital resources.

A clinician facing a similar patient could consider a low-volume combination of an interscalene block and a superficial cervical plexus block with light sedation, with arterial pressure monitoring and a plan for conversion to GA. Several cautions apply. In one study, interscalene injection of 25 mL raised the optic nerve sheath diameter, a surrogate marker of ICP, in 29 of 34 patients.[42] Such surrogates are worth recording after the block. Smaller volumes and phrenic-sparing alternatives, such as a C5 root block with a supraclavicular nerve block, have been described.[32] The advice is transferable mainly to young patients without cardiopulmonary disease, and operator experience is needed to place the injections precisely and to avoid vascular puncture or pneumothorax.

4.5. Strengths

The record is complete for a case report. It holds arterial line pressures and heart rate at 11 time points, the block technique with volumes, sensory, motor and diaphragm assessment, a 48-hour postoperative table and documented consent and ethics approval.

4.6. Limitations

A single case cannot establish causation, efficacy or superiority over general anesthesia. ICP was not measured with a parenchymal transducer or a surrogate such as optic nerve sheath diameter, so the CPP trajectory depends on an assumption. Invasive ICP monitoring was not clinically justified once the patient had recovered neurologically and was stable on CT. Dexmedetomidine, the arterial line and the time course are confounders that cannot be separated from the blocks. Follow-up lasted 48 hours, and no neurological monitoring beyond GCS and pupils was used. The patient was a young man with strong physiological reserve, so the findings may not apply to older patients with cardiopulmonary disease.

4.7. Recommendations for future work

A prospective series would be needed. It should enroll patients with a skull defect or raised ICP, record ICP or its surrogates, diaphragmatic function and neurological outcome, and compare regional with general anesthesia. Such a design could test whether regional anesthesia lowers secondary insults in this population.

5. Conclusion

Clavicle fixation six days after decompressive craniectomy was feasible under ultrasound-guided interscalene and superficial cervical plexus blocks with light dexmedetomidine sedation, without airway instrumentation and with arterial pressure between 83.3 and 93.3 mmHg. ICP was not measured. Dexmedetomidine probably contributed. The case therefore does not show neuroprotection or superiority over general anesthesia, but it justifies a prospective study with ICP monitoring and a comparison group.

6. Declarations

Ethical approval and consent to participate. The protocol was approved by the CMHC Research Center Ethics Committee, Indonesia (protocol number 2025/4108), and followed the Declaration of Helsinki. Written informed consent was obtained from the patient.

Consent for publication. Written informed consent for publication of this case, including de-identified clinical and hemodynamic data, was obtained from the patient. No patient image is shown. A copy of the signed consent form is available for review by the Editor-in-Chief on request.

Availability of data and materials. The de-identified dataset, the longitudinal hemodynamic measurements and the calculation tables supporting this report are contained in the article and are available from the corresponding author on reasonable academic request.

Artificial intelligence (AI) use statement. No generative artificial intelligence tool was used in the preparation of this manuscript.

Author contribution statement. M.H.T. conceived the report, performed the ultrasound-guided blocks and supervised clinical management (Conceptualization, Investigation, Supervision). B.A. contributed to intraoperative data collection and the literature review (Data curation, Investigation). M.D.H. performed the calculations, drafted the manuscript and coordinated submission (Formal analysis, Writing – original draft, Project administration). All authors reviewed and approved the final manuscript (Writing – review & editing).

Funding statement. This research received no specific grant from any funding agency in the public, commercial or not-for-profit sectors.

Conflict of interest (competing interests) statement. The authors declare that they have no competing interests.

Acknowledgments. The authors thank the nursing, anesthesia, orthopedic and neurosurgical teams of the Faculty of Medicine, Universitas Sebelas Maret / Dr. Moewardi General Hospital for their support during patient care and data collection.

7. References

1. Dewan MC, Rattani A, Gupta S, et al. Estimating the global incidence of traumatic brain injury. J Neurosurg. 2019;130(4):1080-1097. doi:10.3171/2017.10.jns17352
2. Wang X, Ge R, Yuan J, et al. Risk Factors and Prognostic Value of Swirl Sign in Traumatic Acute Epidural Hematoma. Front Neurol. 2020;11:543536. doi:10.3389/fneur.2020.543536
3. Meyfroidt G, Bouzat P, Casaer MP, et al. Management of moderate to severe traumatic brain injury: an update for the intensivist. Intensive Care Med. 2022;48(6):649-666. doi:10.1007/s00134-022-06702-4
4. Freire MAM, Rocha GS, Bittencourt LO, et al. Cellular and Molecular Pathophysiology of Traumatic Brain Injury: What Have We Learned So Far?. Biology (Basel). 2023;12(8):1139. doi:10.3390/biology12081139
5. Watanabe T, Kawai Y, Iwamura A, et al. Outcomes after Traumatic Brain Injury with Concomitant Severe Extracranial Injuries. Neurol Med Chir (Tokyo). 2018;58(9):393-399. doi:10.2176/nmc.oa.2018-0116

6. Burnham JM, Kim DC, Kamineni S. Midshaft Clavicle Fractures: A Critical Review. Orthopedics. 2016;39(5):e814-e821. doi:10.3928/01477447-20160517-06
7. Amer K, Smith B, Thomson JE, et al. Operative Versus Nonoperative Outcomes of Middle-Third Clavicle Fractures: A Systematic Review and Meta-Analysis. J Orthop Trauma. 2020;34(1):e6-e13. doi:10.1097/bot.0000000000001602
8. Roberts CJ, Barber J, Temkin NR, et al. Clinical Outcomes After Traumatic Brain Injury and Exposure to Extracranial Surgery. JAMA Surg. 2024;159(3):248-259. doi:10.1001/jamasurg.2023.6374
9. Chandankhede AR, Thombre SD, Shukla D. Correlating Intracranial Pressure Following Decompressive Craniectomy With Neurological Outcomes in Severe Traumatic Brain Injury Patients: A Prospective Observational Study. Cureus. 2023;15(6):e40119. doi:10.7759/cureus.40119
10. Benveniste R, Cajigas I, Jagid J, et al. Intracranial Hypertension After Primary Decompressive Craniectomy for Head Trauma. World Neurosurg. 2022;157:e351-e356. doi:10.1016/j.wneu.2021.10.088
11. Needham E, McFadyen C, Newcombe V, et al. Cerebral Perfusion Pressure Targets Individualized to Pressure-Reactivity Index in Moderate to Severe Traumatic Brain Injury: A Systematic Review. J Neurotrauma. 2017;34(5):963-970. doi:10.1089/neu.2016.4450
12. Donnelly J, Budohoski KP, Smielewski P, et al. Regulation of the cerebral circulation: bedside assessment and clinical implications. Crit Care. 2016;20(1):129. doi:10.1186/s13054-016-1293-6
13. Brasil S, Patriota GC, Godoy DA, et al. Monro-Kellie 4.0: moving from intracranial pressure to intracranial dynamics. Crit Care. 2025;29(1):229. doi:10.1186/s13054-025-05476-7
14. Mosaffa F, Ghasemi M, Habibi A, et al. Efficacy Comparison Between Interscalene Block with and Without Superficial Cervical Plexus Block for Anesthesia in Clavicle Surgery. Anesth Pain Med. 2024;14(1):e142051. doi:10.5812/aapm-142051
15. Kim H. Anesthetic management of the traumatic brain injury patients undergoing non-neurosurgery. Anesth Pain Med (Seoul). 2023;18(2):104-113. doi:10.17085/apm.23017
16. Singh G, LNU H, Verma R, et al. Effects of Intranasal and Intravenous Dexmedetomidine on Hemodynamic Responses to Tracheal Intubation and Skull Pin Holder Fixation: A Double-Blinded, Randomized Controlled Trial. Cureus. 2025:e76980. doi:10.7759/cureus.76980
17. Kwon JH, Shin YH, Gil NS, et al. Effect-site concentration of remifentanil for smooth emergence from sevoflurane anesthesia in patients undergoing endovascular neurointervention. PLoS One. 2019;14(6):e0218074. doi:10.1371/journal.pone.0218074
18. Tulgar S, Ahıskalıoğlu A, Kilicaslan A, et al. Fascial plane blocks as the main anesthetic method: A narrative review. Saudi J Anaesth. 2025;19(2):198-208. doi:10.4103/sja.sja_844_24
19. Leurcharusmee P, Maikong N, Kantakam P, et al. Innervation of the clavicle: a cadaveric investigation. Reg Anesth Pain Med. 2021;46(12):1076-1079. doi:10.1136/rapm-2021-103197
20. Jiang F, Li NN, Yang Y, et al. Ultrasound-guided selective supraclavicular nerve block combined with modified clavipectoral fascial plane block for midshaft clavicule fracture surgery: a case report. BMC Anesthesiol. 2025;25(1):415. doi:10.1186/s12871-025-03300-x
21. Ding X. Regional Anesthesia for Clavicle Fracture Surgery- What is the Current Evidence: A Systematic Review. Open Anesth J. 2022;16(1):e258964582208010. doi:10.2174/25896458-v16-e2208010
22. Liu X, Li Y, Kang L, et al. Recent Advances in the Clinical Value and Potential of Dexmedetomidine. J Inflamm Res. 2021;14:7507-7527. doi:10.2147/jir.s346089
23. Lee CCM, Lua CB, Peng K, et al. Regional Anesthetic and Analgesic Techniques for Clavicle Fractures and Clavicle Surgeries: Part 2—A Retrospective Study. Healthcare (Basel). 2022;10(10):1987. doi:10.3390/healthcare10101987
24. Wibowo KAT, Ihsaniar A, Thamrin H. Ultrasound-Guided Regional Anesthesia for Clavicle Fixation in a Pregnant Patient with Traumatic Brain Injury: A Case Report and Pathophysiological Review. Open Access Indones J Med Rev. 2025;5(6):1623-1636. doi:10.37275/oaijmr.v5i6.797
25. Riley DS, Barber MS, Kienle GS, et al. CARE guidelines for case reports: explanation and elaboration document. J Clin Epidemiol. 2017;89:218-235. doi:10.1016/j.jclinepi.2017.04.026
26. Ramos MB, Britz JPE, Telles JPM, et al. The Effects of Head Elevation on Intracranial Pressure, Cerebral Perfusion Pressure, and Cerebral Oxygenation Among Patients with Acute Brain Injury: A Systematic Review and Meta-Analysis. Neurocrit Care. 2024;41(3):950-962. doi:10.1007/s12028-024-02020-3
27. Okumus O, Dogan AR, Can B. Ultrasound-guided supraclavicular nerve and interscalene block for clavicle surgery in pregnancy: A case report and case-based literature review. Challenge J Perioper Med. 2025;3(2):65. doi:10.20528/cjpm.2025.02.007
28. Khadka R, Lamichhane B, Pandey D, et al. Regional anesthesia as a safe anesthesia technique for clavicle surgery in a COVID-19 positive patient at rural setup. Int J Surg Case Rep. 2022;92:106855. doi:10.1016/j.ijscr.2022.106855
29. Kuntoadi D, Utama SP, Yuliana F, et al. Peripheral Nerve Block as A Safer Alternative than General Anesthesia in High-Risk Patients with Multiple Comorbidities: A Case Report. Solo J Anesth Pain Crit Care. 2025;5(1):115. doi:10.20961/soja.v5i1.95022
30. Pinto LDC, Silva CHRD, Gonçalves PMSE, et al. Supraclavicular nerve and superior trunk block for surgical treatment of clavicle fracture in a patient with Steinert's disease – Case report. Braz J Anesthesiol. 2019;69(1):99-103. doi:10.1016/j.bjane.2018.06.011
31. Diwan S, Nair A, Sermeus LA, et al. Low-Volume Local Anesthetics for C5 and Supraclavicular Nerve Blocks for Mid and Lateral Clavicle Surgery: A Case Series. A A Pract. 2020;14(12):e01322. doi:10.1213/xaa.0000000000001322
32. Abdelghany MS, Ahmed SA, Afandy ME. Superficial cervical plexus block alone or combined with interscalene brachial plexus block in surgery for clavicle fractures: a randomized clinical trial. Minerva Anestesiol. 2021;87(5). doi:10.23736/s0375-9393.21.14865-5
33. Lamade AM, Anthonymuthu TS, Hier ZE, et al. Mitochondrial damage & lipid signaling in traumatic brain injury. Exp Neurol. 2020;329:113307. doi:10.1016/j.expneurol.2020.113307
34. Donnelly J, Beqiri E, Zeiler FA, et al. Secondary insults prevalence, co-occurrence and relationship with outcome after severe TBI. Brain Spine. 2024;4:102764. doi:10.1016/j.bas.2024.102764
35. Benson JC, Madhavan AA, Cutsforth-Gregory JK, et al. The Monro-Kellie Doctrine: A Review and Call for Revision. AJNR Am J Neuroradiol. 2023;44(1):2-6. doi:10.3174/ajnr.a7721
36. Lai HY, Lee CH, Lee CY. The Intracranial Volume Pressure Response in Increased Intracranial Pressure Patients: Clinical Significance of the Volume Pressure Indicator. PLoS One. 2016;11(10):e0164263. doi:10.1371/journal.pone.0164263
37. Rath G, Khandelwal A, Bithal P. Anesthetic considerations for extracranial injuries in patients with associated brain trauma. J Anaesthesiol Clin Pharmacol. 2019;35(3):302-311. doi:10.4103/joacp.joacp_278_18
38. Stundner O, Meissnitzer M, Brummett CM, et al. Comparison of tissue distribution, phrenic nerve involvement, and epidural spread in standard- vs low-volume ultrasound-guided interscalene plexus block using contrast magnetic resonance imaging: a randomized, controlled trial. Br J Anaesth. 2016;116(3):405-412. doi:10.1093/bja/aev550
39. Taha AM, Yurdi NA, Elahl MI, et al. Diaphragm-sparing effect of the infraclavicular subomohyoid block vs low volume interscalene block. A randomized blinded study. Acta Anaesthesiol Scand. 2019;63(5):653-658. doi:10.1111/aas.13322
40. Tao Z, Li P, Zhao X. Progress on the Mechanisms and Neuroprotective Benefits of Dexmedetomidine in Brain Diseases. Brain Behav. 2024;14(11):e70116. doi:10.1002/brb3.70116
41. Safaric Oremus Z, Bradic N, Gospic I, et al. Effect of Dexmedetomidine on Cardiopulmonary Bypass Induced Inflammatory Response in Patients Undergoing Aortic Valve Replacement. Life (Basel). 2025;15(4):524. doi:10.3390/life15040524
42. Gundogdu O, Avci O. Evaluation of the Effect of Interscalene Brachial Plexus Block on Intracranial Pressure Using Optic Nerve Sheath Diameter and Internal Jugular vein Collapsibility Index. J Coll Physicians Surg Pak. 2022;32(10):1249-1254. doi:10.29271/jcpsp.2022.10.1249